

CONTINUING MEDICAL EDUCATION ΣΥΝΕΧΙΖΟΜΕΝΗ ΙΑΤΡΙΚΗ ΕΚΠΑΙΔΕΥΣΗ

Vascular Diseases Quiz – Case 59

A 75-year-old patient with a history of arterial hypertension was admitted to our department due to acute onset of dizziness and dysarthria which were resolved within 10 minutes. Computed tomography (CT) scan did not show any acute focal lesion, while cardiovascular examination excluded cardiac source of emboli. Carotid ultrasonography (CUS) did not detect severe internal carotid artery (ICA) stenosis; thus subsequent CT angiography was performed (figures 1, 2).

What is the most likely diagnosis?

What is the optimal treatment?

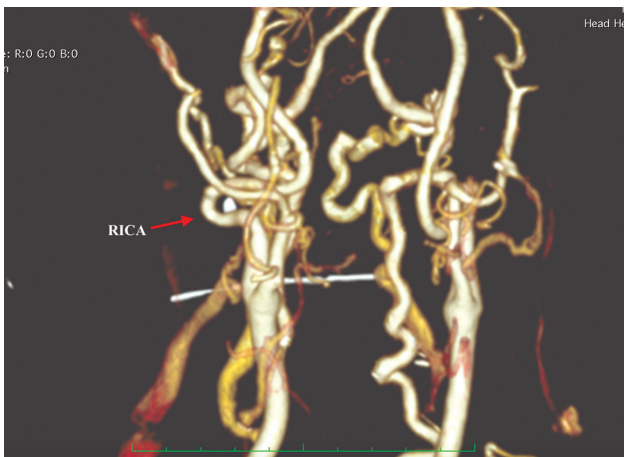


Figure 1

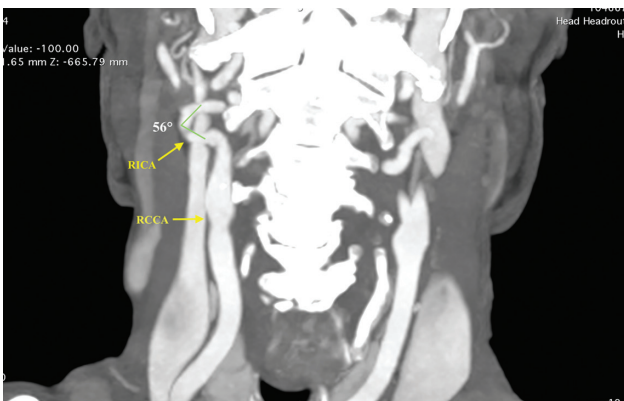

Figure 2

ARCHIVES OF HELLENIC MEDICINE 2021, 38(3):431–432
ΑΡΧΕΙΑ ΕΛΛΗΝΙΚΗΣ ΙΑΤΡΙΚΗΣ 2021, 38(3):431–432

N. Hasemaki,
A. Scotsimara,
A. Giosdekos,
C. Klonaris

First Department of Surgery, Vascular
Division, "Laiko" General Hospital,
Medical School, National and
Kapodistrian University of Athens,
Athens, Greece

Comment

Kinking of the extracranial ICA is defined as an angulation of <math><60</math> degrees of the artery due to elongation, which may cause disturbances in the blood flow to the brain.¹ The incidence of carotid kinking ranges between 10% and 16%.^{1,2} Beigelman³ reported that carotid artery kinking and coiling occur as a result of alterations in embryological development, rather than vascular remodeling secondary to aging and or atherosclerosis. Carotid artery kinking is a silent disorder in most of the cases; however ICA kinking is often related with cerebrovascular events due to flow reduction caused by head torsion or concomitant plaque embolization. Symptoms include transient ischemic attacks, dizziness and stroke, while there are few cases in the literature, reporting dysphagia due to carotid kinking.⁴ According to European Society for Vascular Surgery (ESVS) guidelines,⁵ symptomatic patients with isolated coils/kinks that provided no other cause for symptoms may be considered for surgical correction following multi-disciplinary team review.

References

1. CIOFFI FA, MEDURI M, TOMASELLO F, BONAVITA V, CONFORTI P. Kinking and coiling of the internal carotid artery: Clinical-statistical observations and surgical perspectives. *J Neurosurg Sci* 1975, 19:15–22
2. METZ H, MURRAY-LESLIE RM, BANNISTER RG, BULL JW, MARSHALL J. Kinking of the internal carotid artery. *Lancet* 1961, 1:424–426
3. BEIGELMAN R, IZAGUIRRE AM, ROBLES M, GRANA DR, AMBROSIO G, MILEI J. Are kinking and coiling of carotid artery congenital or acquired? *Angiology* 2010, 61:107–112
4. OZTAS DM, MERIC M, BASARAN B, ERDINC I, OZGUR E, UMTULU M ET AL. A rare and subtle etiology of chronic oropharyngeal pain: Isolated internal carotid artery kinking without stenosis. *Ann Vasc Surg* 2020, 62:496.e15–496.e18

5. NAYLOR AR, RICCO JB, DE BORST GJ, DEBUS S, DE HARO J, HAL-LIDAY A ET AL. Editor's choice – management of atherosclerotic carotid and vertebral artery disease: 2017 clinical practice guidelines of the European Society for Vascular Surgery (ESVS). *Eur J Vasc Endovasc Surg* 2018, 55:3–81

Corresponding author:

C. Klonaris, First Department of Surgery, Vascular Division, "Laiko" General Hospital, Medical School, National and Kapodistrian University of Athens, 115 27 Athens, Greece
e-mail: chris_klonaris@yahoo.com

.....
Diagnosis: Kinking of the extracranial internal carotid artery (ICA)
Answers: (A) Carotid artery kinking; (B) Surgical reconstruction