

## CASE REPORT

## ΕΝΔΙΑΦΕΡΟΥΣΑ ΠΕΡΙΠΤΩΣΗ

# Endovascular treatment of iatrogenic uterine artery pseudoaneurysm A report of two cases

Uterine artery pseudoaneurysm (UAP) is a rare but potentially life-threatening vascular lesion, which may cause secondary postpartum hemorrhage. We report two cases of patients with UAP, aged 31 and 34 years, respectively. Both suffered from secondary postpartum hemorrhage and the diagnosis of left UAP was confirmed on Doppler ultrasound (US). They were both treated successfully with unilateral embolization with gel foam and coiling of the left uterine artery. On follow-up on the 2nd, 4th, 12th, and 24th weeks after surgery no complications were observed. Embolization of the uterine artery is a safe, effective procedure for managing postpartum hemorrhage resulting from UAP, in view of its low complication rate and high success rate. With accurate early diagnosis of UAP and using minimally invasive procedures in appropriately selected cases, the uterus and reproductivity can be preserved using a simple, safe, procedure with a lower complication rate.

Uterine artery pseudoaneurysm (UAP) is a rare but severe vascular lesion<sup>1</sup> that develops when blood flows through the arterial wall after vascular damage<sup>2</sup> caused by trauma, surgery, neoplasm, or infection.<sup>3</sup> UAP typically presents as delayed postpartum hemorrhage, occurring between more than 24 hours to 6 weeks after delivery. Due to its rarity, the actual prevalence rate remains unknown,<sup>4</sup> but it accounts for about 3% of cases of delayed postpartum hemorrhage.<sup>1</sup>

The incidence of UAP has been increasing, so it is important to be aware of this pathology, since the delayed diagnosis of UAP can cause fatal hemorrhage after rupture.<sup>3</sup> UAP may occur after traumatic delivery, manual placenta removal, forceps delivery, use of intrauterine devices, vacuum extraction, dilatation and curettage (D and C), and various gynecological and obstetric surgical procedures, including cesarean section (CS), hysterectomy and myomectomy.<sup>1,3,5</sup>

Although UAP is rare, it must not be neglected. It may show atypical presentation that may be deceptive to obstetricians who are facing an emergency. Emergency

laparotomy may be needed in the case of massive uterine hemorrhage from a UAP.<sup>1</sup>

The clinical presentation of UAP varies; it may present with symptoms such as abdominal or pelvic pain, vaginal bleeding, hypovolemic shock, or fever if there is infection. In some cases it can be asymptomatic, which is why the diagnosis of a UAP is difficult.<sup>1,5</sup> Color Doppler ultrasound (US), magnetic resonance imaging (MRI), computed tomography (CT), and angiography are the usual imaging techniques used to diagnose UAP.<sup>3</sup>

Previously, UAPs were managed by laparotomy, with internal iliac or uterine artery ligation, revision with packing, or hysterectomy when other treatments failed.<sup>1,2</sup>

Recently, uterine artery embolization has proved to be a highly effective safe alternative method for treating UAPs in hemodynamically stable patients.<sup>2</sup>

We report the cases of two patients with UAP presenting with secondary postpartum hemorrhage after CS delivery, both of whom were successfully managed with unilateral

ARCHIVES OF HELLENIC MEDICINE 2020, 37(5):699–703  
ΑΡΧΕΙΑ ΕΛΛΗΝΙΚΗΣ ΙΑΤΡΙΚΗΣ 2020, 37(5):699–703

H. Hemmati,  
M. Mousavi,  
M. Sarrafi

Razi Clinical Research Development  
Unit, Razi Hospital, Guilan University  
of Medical Sciences, Rasht, Iran

Ενδαγγειακή θεραπεία  
του ιατρογενούς  
ψευδοανευρύσματος της μητρικής  
αρτηρίας: Περιγραφή περίπτωσης

Περίληψη στο τέλος του άρθρου

### Key words

Doppler ultrasound  
Embolization  
Pseudoaneurysm  
Secondary postpartum  
hemorrhage  
Uterine artery embolization

Submitted 7.4.2020

Accepted 16.5.2020

embolization of the left uterine artery with coil and gel foam.

## CASE PRESENTATION

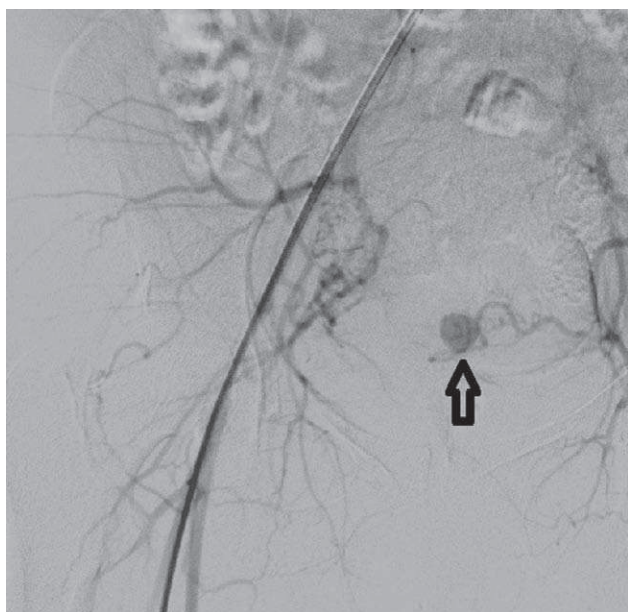### Case 1

A 31-year-old woman, gravida 2 para 2, was referred to the hospital, 18 days post-CS with postpartum hemorrhage. She had undergone elective CS because of previous CS. She was asymptomatic for 10 days post-operation and then experienced two severe vaginal bleeds with clots and was readmitted for further evaluation. She had no significant medical history, and her current medication included oral iron and prenatal vitamins.

She was hemodynamically stable. On abdominal examination, the CS scar was normal with no signs of infection, i.e., tenderness, erythema or hematoma. She denied having fevers, chills, and abdominal or pelvic pain. Pelvic examination revealed a normal vagina and cervix without any lesions. The cervical os was closed and no cervical motion or tenderness was noted. The uterus was bulky, and there was bleeding during speculum examination. Her hemoglobin (Hb) level was 10.5 g/dL (range 12.0–16.0 g/dL). She was stabilized with crystalloids.

Transvaginal US showed extension of a hematoma in the inferior segment of the uterus measuring 40×30×30 mm. Color Doppler sonography showed yin and yang blood flow patterns, indicative of a pseudoaneurysm.

To preserve the fertility in this patient, transcatheter arterial embolization of the pseudoaneurysm was planned. She underwent selective angiography which located the left UAP (fig. 1).



**Figure 1.** Uterine artery pseudoaneurysm in a 31-year-old woman following cesarean section: Selective left internal iliac angiogram showing the pseudoaneurysm (arrow), arising from the left uterine artery.

The left uterine artery was embolized with gel foam followed by application of a Cook stainless steel coil measuring 5×80 mm. Post-embolization angiography confirmed the total obliteration of the vessel (fig. 2). The procedure was performed without any complications, and the patient recovered quickly and was discharged two days later.

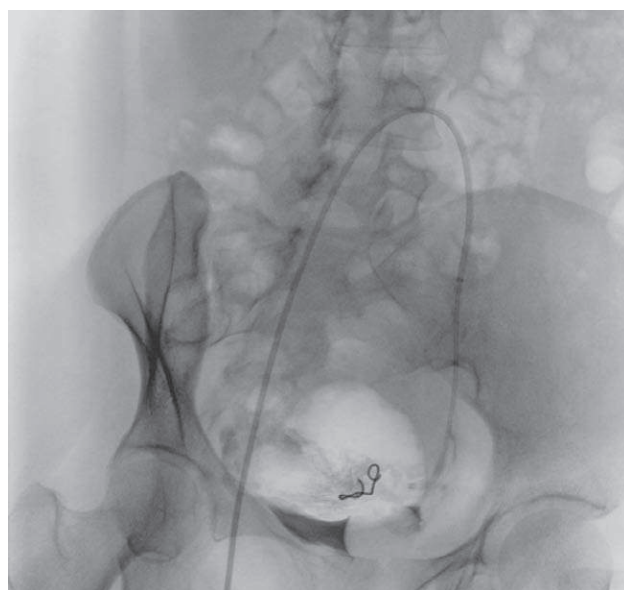
Follow-up color Doppler US showed no evidence of blood flow in the aneurysmal cavity, which was filled with an echogenic content. The only complication was pain in the abdomen, managed with analgesics. She was followed up on the 2nd, 4th, 12th and 24th weeks after surgery and no complications were observed, and serial US were normal.

### Case 2

A 34-year-old woman, gravida 2 para 2, both deliveries via CS was admitted after an episode of severe vaginal bleeding, having experienced multiple episodes of vaginal bleeding with clots over the past 1 month, not associated with cramping, abdominal pain, fever, chills, headache, or dysuria. Her medical history revealed G6PD deficiency.

On examination, the patient was hemodynamically stable, and the abdomen was soft, not distended and not tender. Pelvic examination revealed no labial, vaginal, or cervical lesion, and speculum examination revealed a few small blood clots in the vagina. There were no signs of fresh bleeding. The initial laboratory evaluation revealed a negative pregnancy test, normal prothrombin time, and Hb 10.6 g/dL (range: 12.0–16.0 g/dL).

Transvaginal US showed a hypoechoic, pulsating structure, approximately 20×15 mm in size, with internal yin yang flow (bi-



**Figure 2.** Uterine artery pseudoaneurysm in a 31-year-old woman: Selective left internal iliac angiogram post-embolization, using gel foam and embolization coil, showing complete obliteration of the pseudoaneurysm.

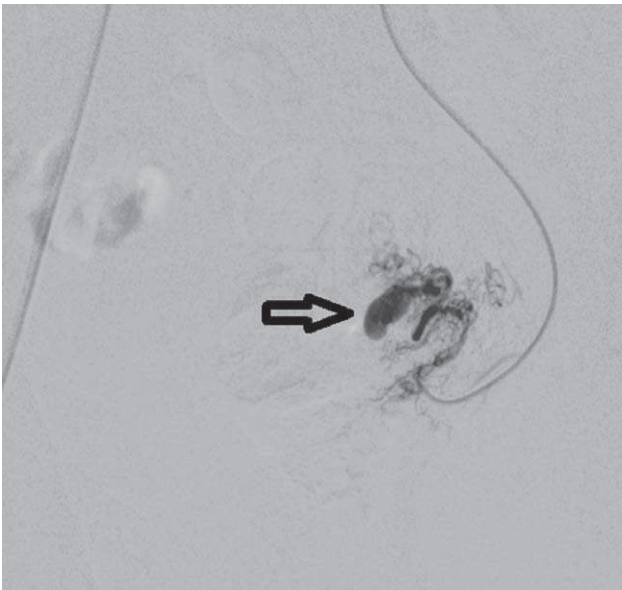
directional, swirling blood flow) on Doppler images, suggestive of a UAP, located on the left side of the uterine fundus.

To preserve fertility in this patient, embolization of the left UAP was programmed. She underwent selective angiography which revealed a pseudoaneurysm from the left uterine artery (fig. 3). The left uterine artery was selectively embolized with gel foam, followed by application of a Cook stainless steel coil measuring 5×80 mm. Post-embolization angiography indicated the complete obliteration of the vessel (fig. 4). Follow-up US revealed a completely thrombosed pseudoaneurysm with no flow. No complications occurred during surgery or postoperatively, and she was discharged two days after the procedure with no bleeding or episodes of hemodynamic instability. She was followed-up on the 2nd, 4th, 12th, and 24th weeks after surgery, at which time she was in good health and had returned to normal activities, with normal regular periods and no residual symptoms from the aneurysm or the embolization. Serial transvaginal, pelvic, and transabdominal US studies were normal.

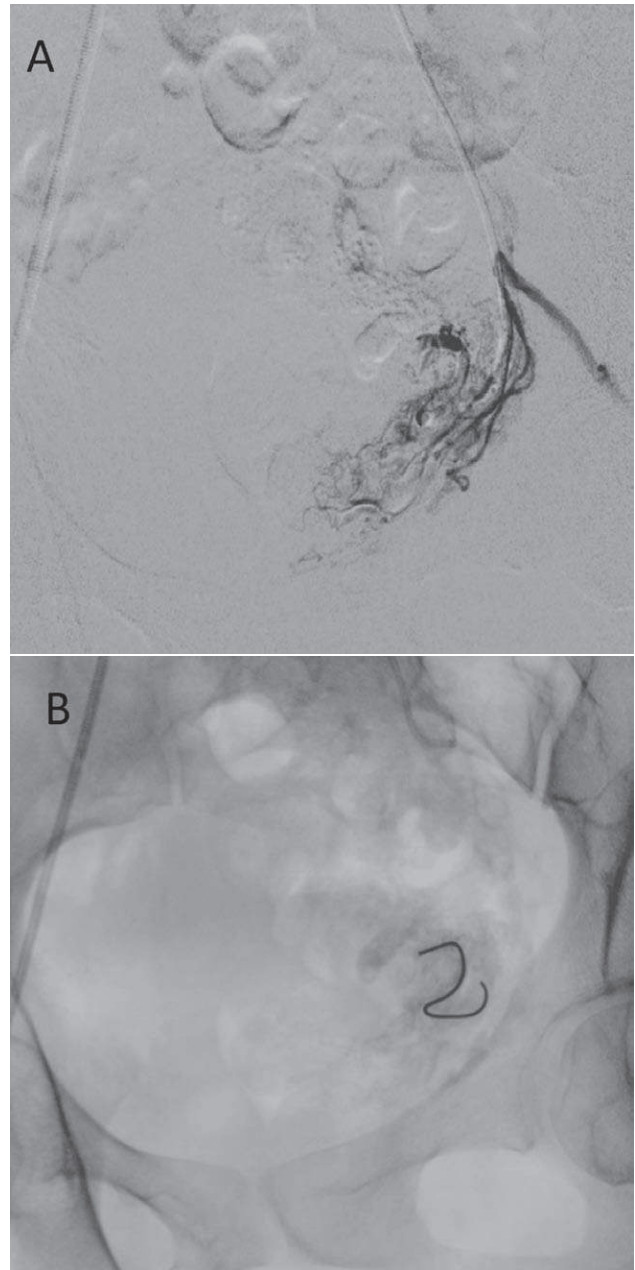
Both patients provided consent for their cases to be shared in a case report format for medical education purposes.

## DISCUSSION

UAP is one of the causes of postpartum hemorrhage, and is of great importance because of the variety of its clinical presentations and the unpredictability of its rupture and resulting bleeding, which can occur within a week of, or months after its development.<sup>7</sup> Contrary to earlier reports, UAP is not rare, but occurs in 2–3/1,000 deliveries, and a



**Figure 3.** Uterine artery pseudoaneurysm in a 34-year-old woman: Selective left internal iliac angiogram showing the pseudoaneurysm (arrow), arising from the left uterine artery.



**Figure 4.** Uterine artery pseudoaneurysm in a 34-year-old woman: Selective left internal iliac angiogram post-embolization using gel foam and embolization coil, showing complete obliteration of the pseudoaneurysm. (A) Post gel foam angiogram and (B) embolization coil within the pseudoaneurysm.

significant percentage after non-traumatic deliveries and abortions.<sup>6</sup>

Rapid, accurate diagnosis of UAP with the help of color Doppler US and CT is necessary to avoid life-threatening bleeds.<sup>3</sup> Color Doppler US is the most useful and safest tool to diagnose pseudoaneurysms during pregnancy.<sup>2</sup> Because of its high sensitivity in depicting blood flow, it is

effective in the diagnosis of UAP (swirling blood flow within an anechoic sac-like structure) although it has limitations, such as inability to detect the supplying artery.<sup>1</sup> With the help of color Doppler US and clinical expertise, maternal mortality due to uterine artery bleeds can be minimized.<sup>7</sup> Angiography remains the standard method of confirming the diagnosis and site of UAP and planning the definitive treatment.<sup>1</sup>

Previously, uterine artery aneurysms were managed by laparotomy, with internal iliac or uterine artery ligation and revision with packing, or hysterectomy when other treatments failed.<sup>1,2</sup> The first case of postpartum hemorrhage treated with uterine artery embolization (UAE) was reported by Brown and colleagues in 1979,<sup>8</sup> since when it has become established as a successful, safe and efficient way to handle postpartum bleeds, as evidenced by numerous reports.<sup>1-3,7,9-11</sup> In addition, Ugwumadu and colleagues also demonstrated that selective unilateral UAE can be tolerated by the fetus and is a useful way of prolonging the pregnancy safely and reducing the risk of preterm labor.<sup>2</sup>

UAP must be considered in the differential diagnosis of secondary postpartum hemorrhage and must be considered in patients complaining of pelvic pain and pelvic bleeds, especially after CS.<sup>10</sup> Transcatheter embolization in both hemodynamically stable and unstable patients is considered the treatment of choice, because of its high success rate and its rare complications, which include organ ischemia, neuropathy, muscle pain, and post-embolization syndrome,<sup>1,12</sup> and also because it can preserve fertility in women of reproductive age.<sup>7,11</sup> Embolization of the

uterine artery can be achieved using a variety of different materials, including as a mixture of gel foam and contrast media,<sup>7,11</sup> absorbable gelatin sponge,<sup>3</sup> gelatin particles,<sup>9</sup> polyvinyl alcohol particles, platinum micro coils,<sup>1</sup> a series of micro coils<sup>2</sup> or a combination of gel foam and coil, as in the present study. It can be unilateral,<sup>1-3,9,10</sup> or bilateral<sup>7,11</sup> depending on the case.

Our cases showed no differences from cases reported before;<sup>1,4,11</sup> they were diagnosed by their history and with the help of US and angiography. The clinical course was the same and we applied the same methods of management, so this report is a confirmation of the standard diagnostic and treatment strategies.

UAE is a safe and effective procedure for treating UAPs, in view of its low complication rate and high success rate. With accurate early diagnosis of UAP and using minimally invasive procedures, a patient who may otherwise lose her uterus in the event of open surgery due to severe bleeding, can be offered both preservation of her uterus and reproductivity, and a simpler, safer procedure with less complications.

#### ACKNOWLEDGMENTS

*We would like to show our gratitude to Razi Clinical Research Development Unit that greatly assisted us in publishing the research.*

*We also thank anonymous reviewers for their valuable insights.*

#### ΠΕΡΙΛΗΨΗ

##### Ενδαγγειακή θεραπεία του ιατρογενούς ψευδοανευρύσματος της μητρικής αρτηρίας: Περιγραφή περίπτωσης

H. HEMMATI, M. MOUSAVI, M. SARRAFI

*Razi Clinical Research Development Unit, Razi Hospital, Guilan University of Medical Sciences, Rasht, Ιράν*

*Αρχεία Ελληνικής Ιατρικής 2020, 37(5):699–703*

Τα ψευδοανευρύσματα της μητρικής αρτηρίας (UAP) είναι σπάνια αλλά δυνητικά μπορεί να προκαλέσουν απειλητικές για τη ζωή αγγειακές βλάβες και αποτελούν σπάνιες αιτίες δευτερογενούς αιμορραγίας μετά τον τοκετό. Περιγράφονται δύο ασθενείς με UAP (31 και 34 ετών, αντίστοιχα), οι οποίες παρουσίασαν δευτερογενή αιμορραγία μετά τον τοκετό και διαγνώστηκαν με UAP σε υπερηχογράφημα Doppler. Αντιμετωπίστηκαν επιτυχώς με εμβολισμό με αφρό γέλης. Οι ασθενείς παρακολούθηθηκαν τη 2η, 4η, 12η και 24η εβδομάδα μετά τη χειρουργική επέμβαση και δεν παρατηρήθηκαν επιπλοκές. Ο εμβολισμός της μητρικής αρτηρίας είναι μια ασφαλής και αποτελεσματική διαδικασία για την αντιμετώπιση της αιμορραγίας μετά τον τοκετό λόγω ψευδοανευρύσματος, λαμβάνοντας υπ' όψη το χαμηλό ποσοστό επιπλοκών και το υψηλό ποσοστό επιτυχίας. Ως εκ τούτου, με την ακριβή έγκαιρη διάγνωση του UAP και εφαρμόζοντας ελάχιστα επεμβατικές διαδικασίες σε κατάλληλα επιλεγμένες περιπτώσεις είναι

εφικτή η διατήρηση τόσο της μήτρας όσο και της αναπαραγωγικότητας της γυναίκας με μια απλή και ασφαλή μέθοδο, χωρίς πολλές επιπλοκές.

**Λέξεις ευρητήριο:** Δευτεροπαθής αιμορραγία μετά τον τοκετό, Εμβολισμός, Εμβολισμός μητρικής αρτηρίας, Υπέρηχος Doppler, Ψευδοανεύρυσμα

## References

- BOI L, SAVASTANO S, BEGHETTO M, DALL'ACQUA J, MONTENEGRO GM. Embolization of iatrogenic uterine pseudoaneurysm. *Gynecol Minim Invasive Ther* 2017, 6:85–88
- UGWUMADU L, HAYES K, BELLI AM, HEENAN S, LOFTUS I. Uterine artery pseudoaneurysm requiring embolization in pregnancy: A case report and review of the literature. *CVIR Endovasc* 2018, 1:31
- ISONO W, TSUTSUMI R, WADA-HIRAIKE O, FUJIMOTO A, OSUGA Y, YANO T ET AL. Uterine artery pseudoaneurysm after cesarean section: Case report and literature review. *J Minim Invasive Gynecol* 2010, 17:687–691
- PARR K, HADIMOH D A, BROWNING A, MOSS J. Diagnosing and treating postpartum uterine artery pseudoaneurysm. *Proc (Bayl Univ Med Cent)* 2018, 31:56–58
- CIEBIERA M, SLABUSZEWSKA-JÓŹWIAK A, ZARĘBA K, JAKIEL G. Management of uterine artery pseudoaneurysm: Advanced ultrasonography imaging and laparoscopic surgery as an alternative method to angio-computed tomography and transarterial embolization. *Wideochir Inne Tech Maloinwazyjne* 2017, 12:106–109
- MATSUBARA S, TAKAHASHI H. Pseudoaneurysm hidden behind secondary postpartum hemorrhage. *Birth* 2016, 43:184–185
- SHARMA N, GANESH D, DEVI L, SRINIVASAN J, RANGA U. Prompt diagnosis and treatment of uterine arcuate artery pseudoaneurysm: A case report and review of literature. *J Clin Diagn Res* 2013, 7:2303–2306
- BROWN BJ, HEASTON DK, POULSON AM, GABERT HA, MINEAU DE, MILLER FJ Jr. Uncontrollable postpartum bleeding: A new approach to hemostasis through angiographic arterial embolization. *Obstet Gynecol* 1979, 54:361–365
- SEKI T, HAMADA Y, ICHIKAWA T, ONOTA S, NAKATA M, TAKAKURA S. Uterine artery pseudoaneurysm caused by a uterine manipulator. *Gynecol Minim Invasive Ther* 2017, 6:25–27
- JOHANNESSEN L, MASON J, OEHLER MK. Uterine artery pseudoaneurysm bleeding one decade after caesarean section: A case report. *J Obstet Gynaecol Res* 2017, 43:939–942
- NANJUNDAN P, ROHILLA M, RAVEENDRAN A, JAIN V, KHANDELWAL N. Pseudoaneurysm of uterine artery: A rare cause of secondary postpartum hemorrhage, managed with uterine artery embolisation. *J Clin Imaging Sci* 2011, 1:14
- SIEBER PR. Bladder necrosis secondary to pelvic artery embolization: Case report and literature review. *J Urol* 1994, 151:422

### Corresponding author:

H. Hemmati, Razi Hospital, Sardar Jangal street, Rasht city, Gilan province, PC 4144895655, Iran  
e-mail: drhossein.hemmati@gmail.com