

CONTINUING MEDICAL EDUCATION ΣΥΝΕΧΙΖΟΜΕΝΗ ΙΑΤΡΙΚΗ ΕΚΠΑΙΔΕΥΣΗ

Surgery Quiz – Case 26

An otherwise-healthy 71-year-old male patient with a known sizable recurrent left retroperitoneal malignant fibrous histiocytoma under pazopanib (*per os* 800 mg daily) with infiltration of the left ureter under double J stent and the descending colon causing incomplete large bowel obstruction, admitted to the emergency department with symptoms and signs of peritonitis. Abdominal computed tomography (CT) revealed the presence of: (a) a solid 16×10×12 cm left retroperitoneal mass, (b) infiltration of the left ureter with the presence of a double J stent, and (c) infiltration as well as perforation of the descending colon along with a large quantity of free intraperitoneal air, paracolic and pelvic fluid (fig. 1). Emergency laparotomy performed which revealed the presence of descending colon perforation and disseminated feculent peritonitis. The patient submitted to left hemicolectomy with end transverse colostomy and intraoperative saline peritoneal lavage.

What was the cause of bowel perforation?

- (a) Bowel infiltration by the tumor
- (b) Incomplete bowel obstruction
- (c) Vascular endothelial growth factor receptor (VEGFR) inhibitor treatment
- (d) All the above

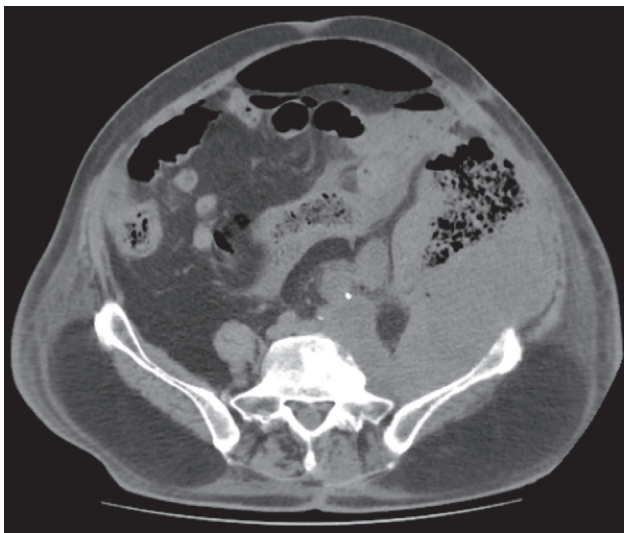


Figure 1

ARCHIVES OF HELLENIC MEDICINE 2020, 37(4):566–567
ΑΡΧΕΙΑ ΕΛΛΗΝΙΚΗΣ ΙΑΤΡΙΚΗΣ 2020, 37(4):566–567

K. Boulas,
A. Paraskeva,
A. Triantafyllidis,
A. Hatzigeorgiadis

Department of General Surgery, General
Hospital of Drama, Drama, Greece

Comment

Spontaneous bowel perforation is a potential complication in patients receiving antiangiogenic treatment. Qi et al in a meta-analysis of 20 clinical trials including 5,352 solid tumors patients receiving VEGFR inhibitors showed that the incidence of gastrointestinal (GI) perforation was 1.3% with a mortality of 28.6%. Among cancer types, the highest incidence of bowel perforation was found in colorectal and ovarian cancer (0.9% and 1%, respectively). Risk factors for antiangiogenic treatment-associated GI perforation are presented in table 1. Complete assessment of risk factors should be performed before starting treatment with the above type of targeted therapy in order the incidence of bowel perforation to be reduced. The presence of active colitis, diverticulitis, peptic ulcer, extensive bowel infiltration and bowel obstruction contraindicates vascular endothelial growth factor (VEGF) and VEGFR inhibitors use.

Table 1. Risk factors related to gastrointestinal (GI) perforation in patients receiving antiangiogenic treatment.

Illnesses	Previous treatments
Bowel obstruction	Abdominal irradiation
Chemotherapy-induced colitis	Bowel surgery
Diverticulitis	NSAID
Peptic ulcer	Steroids
Tumor (intact primary tumor, tumor necrosis, transmural tumor)	Colonoscopy
Abdominal carcinomatosis	
Pancreatic primary cancer	
Ovarian primary cancer	
Rectosigmoid involvement	
Bowel involvement on CT	

CT: Computed tomography; NSAID: Non-steroidal anti-inflammatory drugs

Our patient had a known recurrent left retroperitoneal malignant fibrous histiocytoma. In exploratory laparotomy performed two months prior the presentation; (a) the tumor considered unresectable, (b) preoperative CT staging revealed the presence of left ureter infiltration with associated obstructive hydronephrosis treated palliatively with double J stent placement, (c) preoperative CT and colonoscopy staging revealed the presence of descending colon infiltration with associated incomplete obstruction; however no palliative colostomy performed. Although the patient had risk factors for perforation such as intact primary tumor, bowel infiltration and obstruction, postoperative palliative targeted therapy with pazopanib initiated due to the limited therapeutic options. In conclusion, no adding a colostomy during re-operation, descending colon infiltration and obstruction in combination with VEGFR inhibitor treatment were risk factors that all contributed to colon perforation.

References

1. QIWX, SUNYJ, TANG LN, SHEN Z, YAO Y. Risk of gastrointestinal perforation in cancer patients treated with vascular endothelial growth factor receptor tyrosine kinase inhibitors: A systematic review and meta-analysis. *Crit Rev Oncol Hematol* 2014, 89:394–403
2. PEREZ EA, GUTIERREZ JC, MOFFAT FL Jr, FRANCESCHI D, LIVINGSTONE AS, SPECTOR SA ET AL. Retroperitoneal and truncal sarcomas: Prognosis depends upon type not location. *Ann Surg Oncol* 2007, 14:1114–1122

Corresponding author:

K. Boulas, Department of General Surgery, General Hospital of Drama, Drama, Greece
 e-mail: boulaskonstantinos@gmail.com

.....
Diagnosis: Descending colon perforation as a result of bowel infiltration by the tumor and bowel obstruction in the setting of VEGFR inhibitor treatment