

## CASE REPORT ΕΝΔΙΑΦΕΡΟΥΣΑ ΠΕΡΙΠΤΩΣΗ

---

# Management of thrombosis in a pediatric renal transplant patient with factor VII deficiency A dilemma concerning recombinant factor VIIa

Hemorrhagic complications in surgical patients with congenital factor VII deficiency are a major concern. Replacement therapy is required, in which recombinant factor VIIa is the first treatment choice, by virtue of its higher efficacy and no risk of infection. Because of the risk of vascular thrombosis, recombinant factor VIIa treatment may result in catastrophic outcomes, including graft loss in transplant patients. We present the case of a 7-year-old male who underwent renal transplantation and who developed renal thrombosis after recombinant factor VIIa substitution therapy for factor VII deficiency.

Pediatric renal transplantation is currently the most effective treatment for end stage renal failure in children, and has been performed safely since the 1960s, even in patients with hematological diseases.<sup>1,2</sup> Hemorrhagic complications in surgical patients with congenital factor VII (FVII) deficiency are a major problem, requiring replacement therapy, of which recombinant factor VIIa (rFVIIa) is the first treatment choice by virtue of its higher efficacy and no risk of infection.

Primary non-function, vascular thrombosis and technical problems complicate up to 3.2% of pediatric transplants, and vascular thrombosis accounts for 9.6% of all graft failures.<sup>3</sup> The risk factors for vascular thrombosis can be associated with the donor, the surgical procedure, the graft and the recipient. Due to the risk of vascular thrombosis,

rFVIIa therapy may result in catastrophic outcomes, including graft loss in transplant patients. We present the case of a 7-year-old male who underwent renal transplantation and developed renal thrombosis after rFVIIa substitution therapy for FVII deficiency. Based on a literature search, we believe that this is the first report of thrombotic complications of rFVIIa substitution therapy for FVII deficiency in a pediatric renal transplant patient. Informed consent of the boy's parent was obtained for publication of this report.

### CASE PRESENTATION

A 7-year-old male with FVII congenital deficiency underwent kidney transplantation for end stage renal failure secondary to congenital anomalies of the kidney and urinary tract. He had no

ARCHIVES OF HELLENIC MEDICINE 2020, 37(3):391-394  
ΑΡΧΕΙΑ ΕΛΛΗΝΙΚΗΣ ΙΑΤΡΙΚΗΣ 2020, 37(3):391-394

---

M. Yalcin,<sup>1</sup>  
A. Simsek,<sup>2</sup>  
Y. Tabel,<sup>3</sup>  
S.M. Dogan,<sup>2</sup>  
T. Piskin<sup>2</sup>

---

<sup>1</sup>Department of General Surgery,  
Sanliurfa Mehmet Akif Inan Training  
and Research Hospital, Sanliurfa, Turkey

<sup>2</sup>Department of General Surgery,

<sup>3</sup>Division of Pediatric Nephrology, Turgut  
Ozal Medical Center, School of Medicine,  
Inonu University, Malatya, Turkey

Αντιμετώπιση της θρόμβωσης  
σε ένα παιδί με μεταμόσχευση  
νεφρού και ανεπάρκεια παράγοντα  
VII: Δίλημμα όσον αφορά στον  
ανασυνδυασμένο παράγοντα VIIa

Περίληψη στο τέλος του άρθρου

### Key words

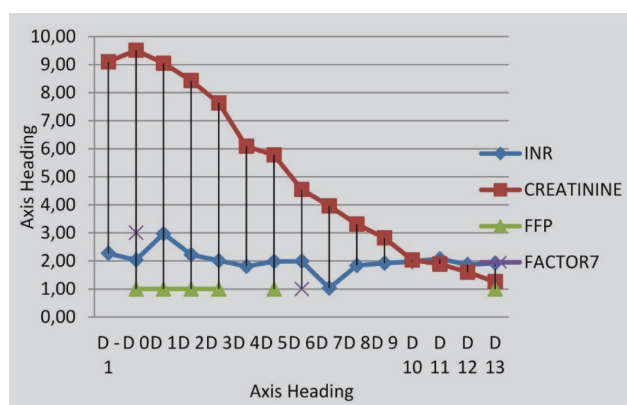
Factor VII deficiency  
Pediatric renal transplantation  
Recombinant factor VIIa  
Renal transplantation  
Thrombosis

Submitted 20.10.2019

Accepted 28.10.2019

history of bleeding, and the FVII deficiency had been discovered when he was 5 years old, during assessment prior to peritoneal dialysis catheter placement.

Preoperative laboratory results revealed: FVII 10.1 mg/dL, activated prothrombin time (aPTT) 19.1 sec, prothrombin time (PT) 26.2 sec, international normalized ratio (INR) 2.27 and a fibrinogen level of 245 mg/dL. The complete blood count was in the normal range. In order to avoid the risk of bleeding, pediatric hematologists and nephrologists recommended administration of rFVIIa (NovoSeven®, Novo Nordisk, Bagsvaerd, Denmark) with a first intravenous dose of 40 mg/kg and a second equal dose after 4 hours. The left kidney of his father was preferred for laparoscopic living donor nephrectomy (LLDN), and was re-perfused by end-to-side anastomoses of the renal artery and vein to the right external iliac artery and vein of the recipient. The urine flow started after 10 minutes. After a while, arterial thrombosis was suspected, based on the decrease in arterial flow and loss of renal tonus. The kidney was explanted immediately and re-flushed. Thrombectomy was performed on both the renal artery and vein. The dissected and deformed parts of the renal artery were resected. Following extension of the renal artery using a cadaveric iliac artery graft, the donor kidney was re-implanted. The sutures placed at the distal end of renal vein anastomosis for hemostasis led to narrowing of the external iliac vein; hence, it was expanded with cadaveric venous graft. The ureter was anastomosed to the bladder and a double J stent was placed. On postoperative follow-up the boy had no major bleeding, apart from a minor epistaxis on the 5th day, which was managed by fresh frozen plasma (FFP) and 0.5 g rFVIIa. Irradiated erythrocyte suspension (ES) was transfused at a dose of 15 mL/kg during the operation and on the first postoperative day. FFP was administered because of changes in the coagulation parameters on postoperative days 1, 2, 3 and 5. Figure 1 shows the laboratory values and medical treatment applied, starting from the 1st day. Immunosuppressive therapy consisted of induction with anti-human T-lymphocyte immunoglobulin, and triple therapy with methylprednisolone, mycophenolate mofetil, and tacrolimus



**Figure 1.** Renal transplantation in a 7-year-old boy with congenital factor VII deficiency: Laboratory values and medical treatment applied. D: Postoperative day, INR: International normalized ratio, FFP: Fresh frozen plasma.

which was added to immunosuppressive protocol on the 4th postoperative day. The patient was discharged on the 15th day.

## DISCUSSION

Congenital FVII deficiency is a rare bleeding disorder with autosomal recessive inheritance. The prevalence of the disease has been reported as 1/300,000–1/500,000 for severe cases, and 1/350 for the heterogeneous form.<sup>4</sup> A mutation of the gene encoded for FVII initiates the extrinsic coagulation pathway by binding with a tissue factor in the area of vascular damage. FVII deficient patients are checked for prothrombin time (PT) and FVII coagulant activity (FVII:C).<sup>5</sup> It is difficult to predict which patients are at risk of bleeding and can take advantage of prophylaxis, since bleeding is weakly correlated with plasma FVII levels. The clinical history is the most reliable parameter for selecting the patients for prophylaxis.<sup>6</sup>

Recombinant factor VIIa was approved for the treatment of hemorrhage and perioperative management in patients with hemophilia A or B with inhibitors, congenital FVII deficiency, acquired hemophilia and Glanzmann's thrombasthenia refractory to platelet transfusions.<sup>5</sup> Its off-label administration also gained popularity since its first application in 1999, although there are no well-established data concerning the safety of such an off-label application.<sup>7</sup> Along with its benefits, rFVIIa may cause thrombosis, which is the most commonly reported adverse effect (incidence of arterial thrombosis: 1/10,000–1/1,000; venous thrombosis: 1/1,000–1/100), leading to even fatal complications.<sup>5</sup> Risk factors for thromboembolic events are not clearly defined for either label or off-label use, although most of the reported thromboembolic complications were secondary to off-label use.<sup>8</sup>

Although this is a rare complication, children may experience significant thrombosis after renal transplantation, which can lead to graft loss. Risk factors for thrombosis include the underlying kidney disease, dialysis type, surgical technique, hypotension, donor/recipient age, cold ischemia time, immunosuppressive therapy and post-transplant infections, etc.<sup>9</sup> Due to the risk of vascular thrombosis, administration of rFVIIa may result in a catastrophic outcome, including graft loss in transplant patients.

There are no accepted guidelines based on multicenter trials to elucidate the optimal dosage of rFVIIa for pediatric patients. As for adults, in whom the dosage is based on body weight, not age, a dose of 15–30 µg/kg every 4–6 hours until hemostasis achieved is recommended for surgical procedures in children with congenital FVII deficiency.<sup>5</sup> As

far as we could ascertain, in the literature only three renal transplant cases (two in adults, and one in a child) have been reported in which rFVIIa was preferred, for both label (one case) and off-label (two cases) usage. A successful renal transplantation was reported in a 53-year-old man treated with rFVIIa for FVII deficiency. The treatment was based on rFVIIa administration in doses tapered empirically at first (30 µg/kg), then on the basis of INR values.<sup>10</sup> An uneventful off-label use of rFVIIa (30 µg/kg in a single dose) was reported for uncontrolled bleeding from injury to the vein during thrombectomy in a 65-year-old man who underwent renal transplantation complicated by thrombosis.<sup>11</sup> Also reported was the off-label use of rFVIIa (135 µg/kg) for massive hemorrhage in a pediatric renal transplant patient, where there was no evidence of anastomotic thrombosis, although higher doses of rFVIIa were used than recommended.<sup>12</sup>

The Seven Treatment Evaluation Registry (STER) evaluating rFVIIa administration schedules of patients with congenital FVII deficiency undergoing major and or minor surgery stated that the current choice was to treat them with 20 µg/kg rFVIIa, repeating infusions (up to 8–10 times) in patients with a history of major bleeding episodes and in those with <3% FVII:C. The authors emphasized that the results were confirmed mainly for major, but not minor surgery. The STER included 61 major and 49 minor surgical procedures, among which only 3 of the major and 1 of the minor surgeries were vascular in origin, and none was a solid organ transplantation.<sup>13</sup> In the literature there are

several studies of off-label use of rFVIIa in cardiovascular surgery. In a retrospective two cohort case control study, Fox and colleagues evaluated the effect of rFVIIa use during damage control resuscitation for vascular trauma, and the impact of therapy on vessel repair. They found that early thrombotic graft failure was associated with technical issues (construction of anastomosis, graft redundancy or intimal damage), and was unrelated to withholding heparin or use of rFVIIa.<sup>14</sup> In a study of a rabbit model with vein grafts it was suggested that higher doses of rFVIIa (90 and 300 µg/kg) led to vascular thrombosis, while lower doses (20 µg/kg) did not.<sup>15</sup>

In the case presented here, we could not clearly define the cause of thrombosis. It may have been secondary to technical issues, such as intimal injury during retrieval surgery or to the prophylaxis with high dose of rFVIIa. We think that rigorous surgical dissection should be performed during donor nephrectomy, and the use of rFVIIa or other thrombotic products in such patients should be planned and applied very carefully. If early thrombotic complications emerge, immediate explantation and re-flushing should be performed to minimize the risk of graft loss. Although conclusions cannot be based on a single case, keeping the FVII at low levels by monitoring the patient with FFP may be preferred to bleeding, though bleeding after renal transplantation continues to be an important concern. Future research is needed to clarify the safety and optimal dosage of rFVIIa in such procedures in order to provide definitive conclusions.

## ΠΕΡΙΛΗΨΗ

### Αντιμετώπιση της θρόμβωσης σε ένα παιδί με μεταμόσχευση νεφρού και ανεπάρκεια παράγοντα VII: Δίλημμα όσον αφορά στον ανασυνδυασμένο παράγοντα VIIa

M. YALCIN,<sup>1</sup> A. SIMSEK,<sup>2</sup> Y. TABEL,<sup>3</sup> S.M. DOGAN,<sup>2</sup> T. PISKIN<sup>2</sup>

<sup>1</sup>Department of General Surgery, Sanliurfa Mehmet Akif Inan Training and Research Hospital, Sanliurfa, <sup>2</sup>Department of General Surgery, Turgut Ozal Medical Center, School of Medicine, Inonu University, Malatya, <sup>3</sup>Division of Pediatric Nephrology, Turgut Ozal Medical Center, School of Medicine, Inonu University, Malatya, Τουρκία

Αρχεία Ελληνικής Ιατρικής 2020, 37(3):391–394

Οι αιμορραγικές επιπλοκές σε χειρουργικούς ασθενείς με συγγενή ανεπάρκεια του παράγοντα VII είναι ένα σημαντικό πρόβλημα που απαιτεί θεραπεία αντικατάστασης, στην οποία ο ανασυνδυασμένος παράγοντας VIIa συνιστά θεραπεία πρώτης επιλογής λόγω μεγαλύτερης αποτελεσματικότητας και αποφυγής του κινδύνου λοίμωξης. Λόγω του κινδύνου αγγειακής θρόμβωσης, ο ανασυνδυασμένος παράγοντας VIIa μπορεί να οδηγήσει σε σοβαρές ανεπιθύμητες ενέργειες, περιλαμβανομένης της απώλειας του μοσχεύματος σε ασθενείς με μεταμόσχευση. Παρουσιάζουμε ένα αγόρι ηλικίας 7 ετών το οποίο υποβλήθηκε σε μεταμόσχευση νεφρού και το οποίο εμφάνισε νεφρική θρόμβωση μετά τη χορήγηση ανασυνδυασμένου παράγοντα VIIa λόγω ανεπάρκειας του παράγοντα VII.

**Λέξεις ευρητηρίου:** Ανασυνδυασμένος παράγοντας VIIa, Ανεπάρκεια παράγοντα VII, Θρόμβωση, Μεταμόσχευση νεφρού

## References

1. PERRY DJ. Factor VII deficiency. *Br J Haematol* 2002, 118:689–700
2. McDONALD RA, WATKINS SL. Progress in renal transplantation for children. *Adv Ren Replace Ther* 1996, 3:60–68
3. NORTH AMERICAN PEDIATRIC RENAL TRIALS AND COLLABORATIVE STUDIES. 2014 annual transplant report. NAPRTCS, 2014
4. BHAVNANI M, EVANS DI. Carriers of factor VII deficiency are not always asymptomatic. *Clin Lab Haematol* 1984, 6:363–368
5. NOVO NORDISK INC. NovoSeven® RT (package insert). Novo Nordisk Inc, Plainsboro, NJ, 2019
6. GIANZILY-BLAIZOT M, BIRON-ANDREANI C, AGUILAR-MARTINEZ P, DE MOELOOSE P, BRIQUEL ME, GOUEMAND J ET AL. Inherited factor VII deficiency and surgery: Clinical data are the best criteria to predict the risk of bleeding. *Br J Haematol* 2002, 117:172–175
7. KENET G, WALDEN R, ELDAD A, MARTINOWITZ U. Treatment of traumatic bleeding with recombinant factor VIIa. *Lancet* 1999, 354:1879
8. O'CONNELL KA, WOOD JJ, WISE RP, LOZIER JN, BRAUN MM. Thromboembolic adverse events after use of recombinant human coagulation factor VIIa. *JAMA* 2006, 295:293–298
9. BOCK ME, BOBROWSKI AE, BHAT R. Utility of thrombophilia screening in pediatric renal transplant recipients. *Pediatr Transplant* 2019, 23:e13314
10. LAPECORELLA M, NAPOLITANO M, LUCCHESI A, PISANI F, CLEMENTE K, RIZZA V ET AL. Management of kidney transplantation in a factor VII-deficient patient: Case report. *Transplant Proc* 2012, 44:2033–2035
11. SANDER M, VON HEYMANN C, KOX WJ, SPIES CD, TÜRK I, LOENING SA ET AL. Recombinant factor VIIa for excessive bleeding after thrombectomy prior to kidney transplantation. *Transplantation* 2004, 77:1912–1913
12. DUNKLEY SM, MACKIE F. Recombinant factor VIIa used to control massive hemorrhage during renal transplantation surgery; vascular graft remained patent. *Hematology* 2003, 8:263–264
13. DI MINNO MND, NAPOLITANO M, DOLCE A, MARIANI G; STER STUDY GROUP. Role of clinical and laboratory parameters for treatment choice in patients with inherited FVII deficiency undergoing surgical procedures: Evidence from the STER registry. *Br J Haematol* 2018, 180:563–570
14. FOX CJ, MEHTA SG, COX ED, KRAGH JF Jr, SALINAS J, HOLCOMB JB. Effect of recombinant factor VIIa as an adjunctive therapy in damage control for wartime vascular injuries: A case control study. *J Trauma* 2009, 66(Suppl 4):S112–S119
15. MAZER CD, LEONG-POI H, CHHINA T, ALFARDAN Z, LAPIERRE H, WANG Z ET AL. Recombinant factor VIIa affects anastomotic patency of vascular grafts in a rabbit model. *J Thorac Cardiovasc Surg* 2011, 142:418–423

### Corresponding author:

A. Simsek, Department of General Surgery, Turgut Ozal Medical Center, School of Medicine, Inonu University, Malatya, Turkey  
 e-mail: draksimsek@yahoo.com.tr