

CONTINUING MEDICAL EDUCATION ΣΥΝΕΧΙΖΟΜΕΝΗ ΙΑΤΡΙΚΗ ΕΚΠΑΙΔΕΥΣΗ

Surgery Quiz – Case 15

A 79-year-old female patient with a history of type 2 diabetes presented to the emergency department owing to hematemesis and melena over the preceding 5 days. Plain chest radiograph depicted a non specific widening of mediastinum. Esophago-gastroduodenoscopy revealed a diffuse, circumferential, white appearing esophageal mucosa with loss of rigidity and without stenotic areas in the middle and distal third of the esophagus (fig. 1). Histology of biopsy specimens revealed evidence of atrophic mucosa, vascular injury and ischemic fibrosis. Cultures of biopsy specimens were negative for fungi and mycobacteria.

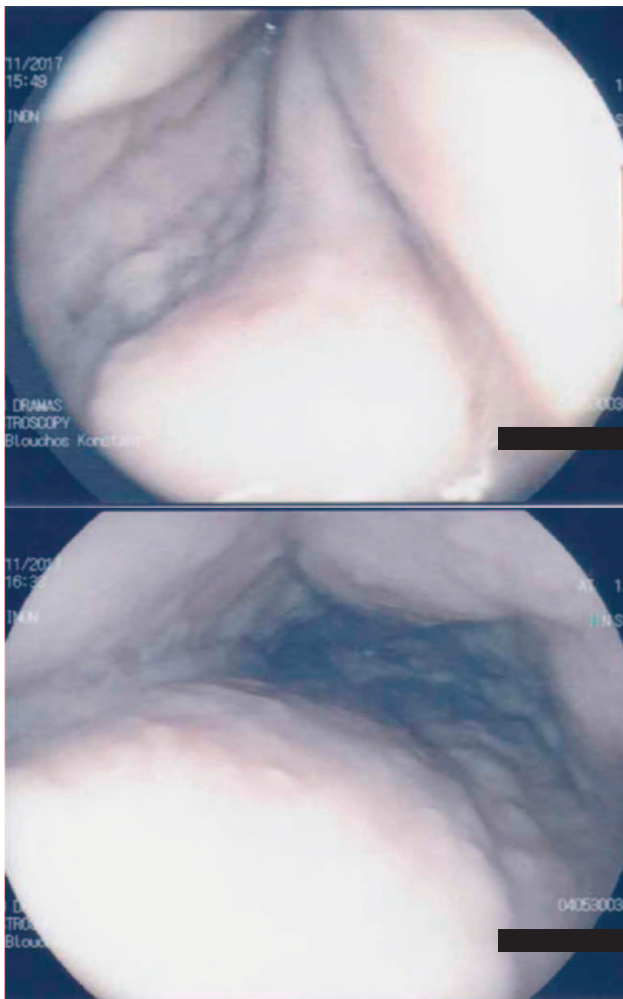


Figure 1. "White" esophagus on endoscopy.

ARCHIVES OF HELLENIC MEDICINE 2018, 35(5):715–716
ΑΡΧΕΙΑ ΕΛΛΗΝΙΚΗΣ ΙΑΤΡΙΚΗΣ 2018, 35(5):715–716

**K. Blouhos,
K. Boulas,
N. Baretas,
A. Paraskeva,
I. Kariotis,
A. Hatzigeorgiadis**

*Department of General Surgery, General
Hospital of Drama, Drama, Greece*

Chest computed tomography (CT) and CT angiogram depicted a diffuse infiltrative soft tissue mass in the posterior mediastinum encasing the esophagus without evidence of pulmonary infiltrations, enlarged lymph nodes, and superior vena cava and pulmonary arteries compression (fig. 2). CT-guided mediastinal Tru-Cut biopsy revealed evidence of a relatively avascular and acellular fibrocollagenous stroma. No clinical, serological, imaging and histological findings of histoplasmosis, pulmonary tuberculosis, sarcoidosis, intrathoracic malignancy and no history of former external thoracic radiation were present.

What is your diagnosis?

Comment

Our patient had a "white" appearing esophagus on endoscopy. Candidiasis, caustic agents, pills such as doxycycline and quinidine, eosinophilic and sloughing esophagitis are common causes that can sometimes produce extensive white plaques and membranes giving the appearance of a "white" esophagus. However, direct

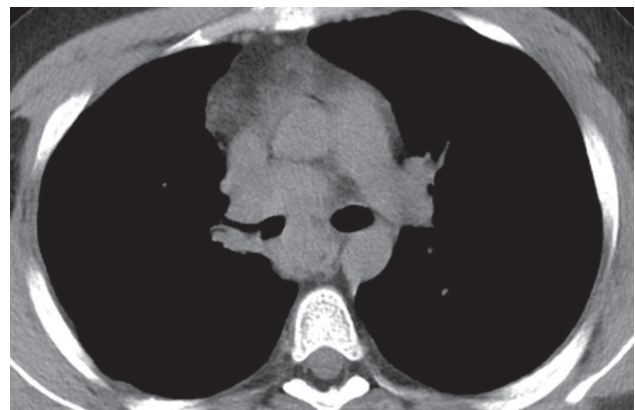


Figure 2. Diffuse infiltrative soft tissue mass in the posterior mediastinum on chest computed tomography (CT).

questioning, clinical course, endoscopy, cultures and histology of biopsy specimens excluded all the above possible causes. Moreover, endoscopic ("white" esophagus with loss of rigidity) and histologic (atrophic mucosa, vascular injury and ischemic fibrosis) findings were highly suggestive of a non specific chronic esophageal ischemia. Our patient had also a widen mediastinum on plain chest radiograph. Chest CT and histology along with the absence of clinical, serological, imaging and histologic findings of histoplasmosis, pulmonary tuberculosis, sarcoidosis, intrathoracic malignancy and history of former external thoracic radiation were highly suggestive of idiopathic mediastinal fibrosis. Consequently, our patient was diagnosed with chronic esophageal ischemia ("white" esophagus on endoscopy) due to idiopathic mediastinal fibrosis and treated conservatively with restriction of oral intake, a proton-pump inhibitor and systemic corticosteroids. Clinical course was uncomplicated and the patient discharged 10 days after admission.

The spectrum of esophageal ischemic injury can be described by the terms black and white esophagus which corresponds to different degrees of acute and chronic ischemic injury, respectively, as a canvas with different degrees in the shade of grey. Esophageal ischemia is extremely rare; less than 100 of acute and only a couple of chronic ischemia cases have been reported in the literature. Chronic ischemia can occur in response to prior major thoracic surgery, external

beam radiation and mediastinal fibrosis, as in our patient's case. Initial approach involves careful assessment of the ischemic injury extent by CT and early endoscopy. Management should follow the rules of caustic injury treatment; the grade of injury on endoscopy appears to be closely correlated with the degree of urgency for surgical intervention, complications development and mortality.

References

1. GURVITS GE, SHAPSIS A, LAU N, GUALTIERI N, ROBILOTTI JG. Acute esophageal necrosis: A rare syndrome. *J Gastroenterol* 2007, 42:29–38
2. KIM DB, BOWERS S, THOMAS M. Black and white esophagus: Rare presentations of severe esophageal ischemia. *Semin Thorac Cardiovasc Surg* 2017, 29:256–259
3. BLASBERG JD. Black esophagus, white esophagus, or shades of gray? *Semin Thorac Cardiovasc Surg* 2017, 29:260–261

Corresponding author:

K. Boulas, Department of General Surgery, General Hospital of Drama, Drama, Greece
e-mail: boulaskonstantinos@gmail.com