

CONTINUING MEDICAL EDUCATION ΣΥΝΕΧΙΖΟΜΕΝΗ ΙΑΤΡΙΚΗ ΕΚΠΑΙΔΕΥΣΗ

Electrocardiogram Quiz – Case 39

A 28-year-old female, known case of rheumatic heart disease since early childhood, presented in the medicine Emergency Room (ER) of Government Medical College and Guru Nanak Dev Hospital with complains of shortness of breath and fatigue since 3–4 hours. Cardiovascular examination revealed normal apical left ventricular (LV) impulse, an accentuated S1, and a diastolic rumble that was heard best at the apex in the left lateral decubitus position. Her chest x-ray taken 5–6 months back showed enlargement of the right atrium, right ventricle, and pulmonary artery. Barring anemia and irregularly irregular pulse, rest of the general physical examination was unremarkable. Abdominal examination was normal, normal vesicular breath sounds were heard over all the lung fields and there was no neurological deficit. Her electrocardiogram (ECG) in the ER showed the following pattern (fig. 1).

What is the most probable diagnosis?

Comment

The strip shows atrial fibrillation with right ventricular hypertro-

ARCHIVES OF HELLENIC MEDICINE 2017, 34(6):849–850
ΑΡΧΕΙΑ ΕΛΛΗΝΙΚΗΣ ΙΑΤΡΙΚΗΣ 2017, 34(6):849–850

G.S. Shergill,
A. Singh,
S. Singh

Department of Medicine, Government
Medical College and Guru Nanak Dev
Hospital, Amritsar, India

phy (suggested by dominant R wave in V1, secondary repolarisation abnormality in the form of T wave inversion in the same lead and massive right axis deviation) which strongly points towards mitral stenosis (MS). Physical examination and later 2d echocardiography confirmed the diagnosis of severe MS.

Mitral stenosis has been known to be associated with characteristic electrocardiographic changes that include left atrial abnormality which may manifest as P mitrale (absent in this case due to associated AF). Almost always associated right ventricular hypertrophy appears as a dominant R wave in V1 and V2, right axis deviation and secondary repolarisation abnormalities in the form of ST-T changes in anterior precordial leads. There may be features of digitalis effects too, if the patient is under treatment with the agent. Mitral stenosis is a very important substrate for the development of atrial fibrillation due to marked left atrial enlargement which further leads to atrial fibrosis. Atrial fibrillation may be present in 60 to 70% of severe MS cases, and this strip is one such classical type.

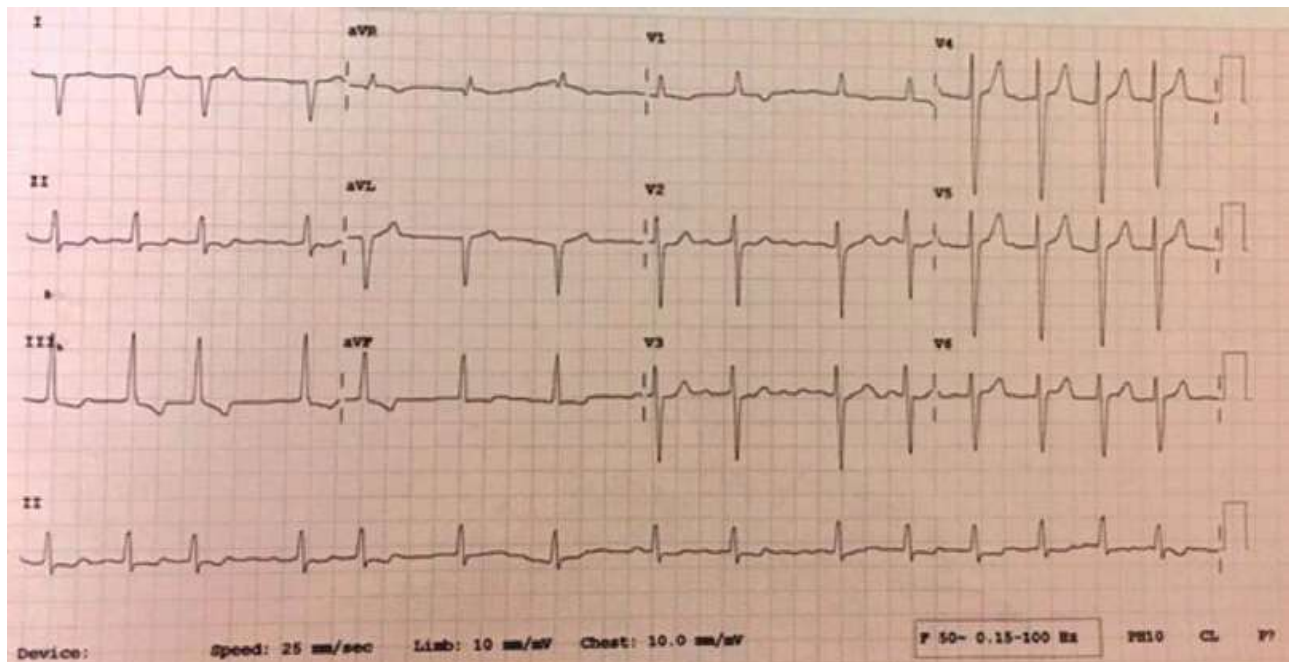


Figure 1

Twice more common in women than men, MS is most commonly caused by rheumatic fever. Other etiologies of MS are rare and include congenital anomalies, severe mitral annular calcification, left atrial myxoma, prior exposure to chest radiation and mucopolysaccharidosis.

References

1. MAGANTI K, RIGOLIN VH, SARANO ME, BONOW RO. Valvular heart disease: Diagnosis and management. *Mayo Clin Proc* 2010,

85:483–500

2. TROUNCE JR. The electrocardiogram in mitral stenosis. *Br Heart J* 1952, 14:185–192
3. GOLDBERGER AL, GOLDBERGER ZD, SHVILKIN A. *Goldberger's clinical electrocardiography: A simplified approach*. 8th ed. Elsevier, India, 2013:46, 222

Corresponding author:

G.S. Shergill, Government Medical College and Guru Nanak Dev Hospital, Amritsar, Pin 143001, Punjab, India
e-mail: drgagandeepshergill@gmail.com