

CONTINUING MEDICAL EDUCATION ΣΥΝΕΧΙΖΟΜΕΝΗ ΙΑΤΡΙΚΗ ΕΚΠΑΙΔΕΥΣΗ

Electrocardiogram Quiz – Case 36

A 61-year-old woman presented to the emergency department of our hospital complaining of mild chest pain of an hour duration. The patient's medical history included arterial hypertension under telmisartan and amlodipine. She was hemodynamically stable with normal vital signs. The initial surface electrocardiogram (ECG) is depicted below.

Questions

- What abnormal ECG findings are present?
- What is the differential diagnosis?

Comment

True posterior myocardial infarction (PMI), the "dead angle infarction" of the ECG, is often misjudged and this may be the reason for undertreatment. It is suggested to be one of the most commonly missed types of acute myocardial infarction (MI) electrocardiographic patterns. Clinically, the condition involves necrosis of the dorsal, infra-atrial part of the left ventricle located beneath the atrioventricular sulcus. PMI usually results from occlusion of the left circumflex coronary artery, as in our patient, but the anatomy can be variable. Occlusion of the right coronary artery may also be the cause, depending on the vessel's dominance.

The electrocardiographic diagnosis is difficult because no specific leads of the standard ECG directly represent this area. However, several ECG criteria have been developed in order to facilitate the diagnosis. These include: ST-segment depression in leads V1–V3, prominent R wave in leads V1–V3, R/S wave ratio >1.0 in lead V2, prominent upright T wave in leads V1–V3, combination of horizontal

ARCHIVES OF HELLENIC MEDICINE 2017, 34(4):574
ΑΡΧΕΙΑ ΕΛΛΗΝΙΚΗΣ ΙΑΤΡΙΚΗΣ 2017, 34(4):574

E. Petrou,
A. Tsipis,
V. Vartela,
G. Athanassopoulos

Division of Cardiology, "Onassis" Cardiac
Surgery Centre, Athens, Greece

ST-segment depression with upright T wave in leads V1–V3, co-existing acute inferior and or lateral MI, ≥ 1 mm ST-segment elevation in additional lead ECG (posterior leads V7 to V9).

Delay in diagnosis can be avoided by recording posterior leads V7–V9, at the level of the tip of the scapula and at the posterior axillary line (V7), a position midway between this and the spine (V8), and a paraspinal lead (V9). Right ventricular hypertrophy can also cause large R waves in the early V leads. Moreover, infarction of the right ventricle is rare but could produce a similar ECG.

References

- VAN GORSELEN EO, VERHEUGT FW, MEURSING BT, OUDE OPHUIS AJ. Posterior myocardial infarction: The dark side of the moon. *Neth Heart J* 2007, 15:16–21
- KHAN JN, CHAUHAN A, MOZDIK E, KHAN JM, VARMA C. Posterior myocardial infarction: Are we failing to diagnose this? *Emerg Med J* 2012, 29:15–18

Corresponding author:

E.G. Petrou, Division of Cardiology, "Onassis" Cardiac Surgery Centre, 356 Sygrou Ave., 176 74 Kallithea, Greece
e-mail: emmgpetrou@hotmail.com

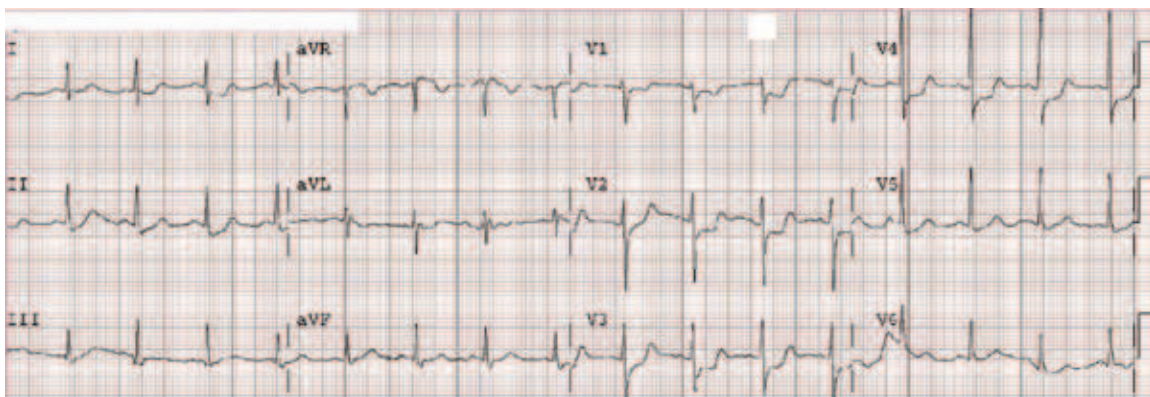


Figure 1

Diagnosis: True posterior myocardial infarction