

## SHORT COMMUNICATION ΒΡΑΧΕΙΑ ΔΗΜΟΣΙΕΥΣΗ

ARCHIVES OF HELLENIC MEDICINE 2017, 34(2):264–266  
ΑΡΧΕΙΑ ΕΛΛΗΝΙΚΗΣ ΙΑΤΡΙΚΗΣ 2017, 34(2):264–266

# Ultrasound evaluation of the thyroid gland in infants and children

T.N. Spyridopoulos,<sup>1</sup> A. Papaioannou<sup>2</sup>

<sup>1</sup>EchoHealth Pediatric and Adult Ultrasound Clinic,  
Athens, Greece

<sup>2</sup>Second Department of Radiology, "Attikon" General  
University Hospital, Athens, Greece

Υπερηχογραφική εκτίμηση του θυρεοειδούς  
αδένα σε παιδιατρικούς ασθενείς

Περίληψη στο τέλος του άρθρου

**Key words:** Children, Pediatric, Thyroid disorders, Thyroid gland, Ultrasound

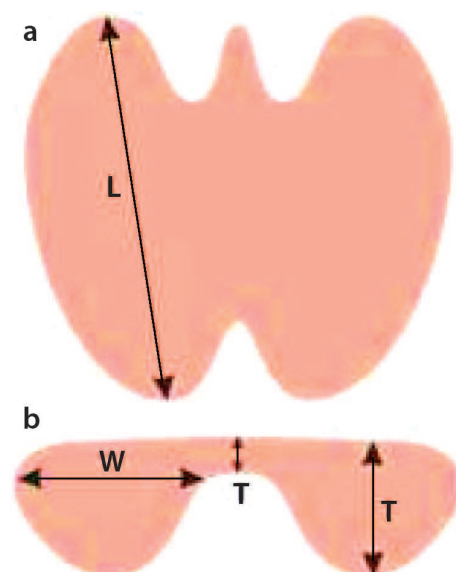
Ultrasonography (US) has a key role in the imaging and evaluation of soft tissue structures of the neck. US is the first line imaging modality for the diagnosis and monitoring of various thyroid abnormalities in the pediatric population, as it is non-invasive, radiation-free and cost effective, and does not require sedation or anesthesia.

Thyroid US reveals if there is thyroid tissue in the expected region of the neck; it enables determination of the size and volume of the gland, which in the newborn infant also defines the mental and physical development, in the case of untreated congenital hypothyroidism.<sup>1</sup> Adjacent structures such as lymph nodes, muscles and vessels are also evaluated.<sup>2</sup> Doppler is a valuable tool for estimation of the vascularity of the thyroid parenchyma.

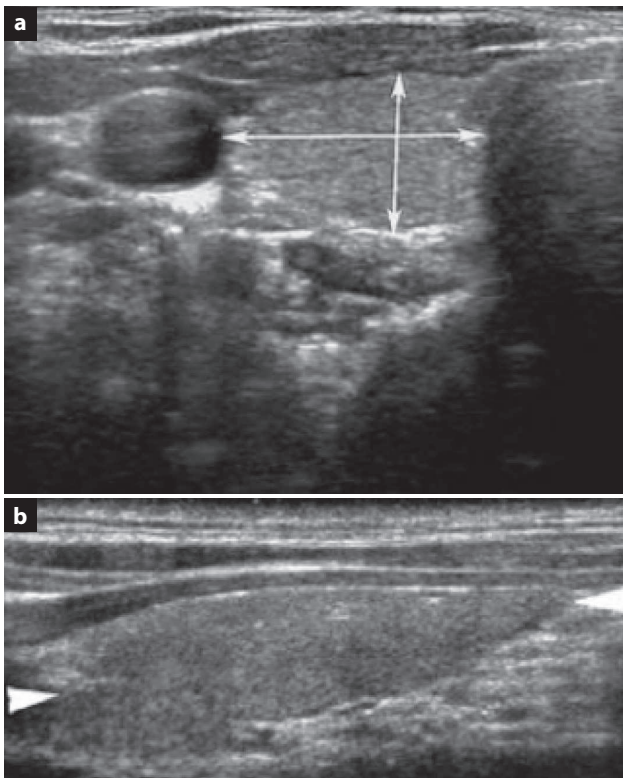
During the thyroid US scan the neonate or child is placed in the supine position, with a small pad under the shoulders for babies with a short neck. As the thyroid gland is a superficial organ, it can be imaged with high frequency linear array transducers 15-MHz to 7-MHz, or in some cases curvilinear transducers.<sup>1,3</sup> The US examination includes im-

ages of the transverse and longitudinal planes. The entire thyroid gland should be examined, although the isthmus is not included in the volumetric evaluation of the gland,<sup>2</sup> unless it is >3 mm.<sup>4</sup> Transverse views are obtained by using certain landmarks, such as the trachea and the neck vessels. Transverse planes are obtained perpendicular to the trachea. Longitudinal planes are obtained along the ovoid shape of the lobes of the gland (fig. 1, figures 2a and 2b).

The thyroid volume is calculated using the formula  $L \times W \times T \times 0.52$ . The volume of the thyroid is correlated with the body weight, height and surface area. It is dependent on the iodine intake, which influences the size of thyroid gland in the case of goiter.<sup>1</sup> There are few reports on the possible influence of smoking on the size of the thyroid gland, and maternal smoking has been associated with an increase in the size of the gland in neonates.<sup>1</sup> In neonates, the thyroid volume measurements range from 472 mm<sup>3</sup> to 1,430 mm<sup>3</sup>.<sup>5</sup>



**Figure 1.** Schematic image showing the basic measurement sites of the thyroid gland. L: Length, W: Width, T: Thickness.



**Figures 2a, 2b.** Transverse and longitudinal ultrasound images, respectively, of the thyroid gland.

Congenital hypothyroidism results from the partial or complete absence of the thyroid gland. Thyroid dysgenesis, dysmorphogenesis and pituitary or hypothalamic hypothyroidism may cause congenital hypothyroidism. Dysgenesis is a morphological thyroid tissue deficit, observed with the various types of thyroid aplasia, hypoplasia and ectopia. When US reveals no thyroid tissue in the expected anatomical position, a search must be made for ectopic thyroid tissue at the base of the tongue, in the mediastinum, and near the heart, the esophagus and the diaphragm. In this case, nuclear scanning must be performed to identify ectopic functioning thyroid tissue.

Thyroid enlargement (goiter) may be the result of maternal thyrotoxicosis, or the intake of iodine or other goitrogens (e.g., lithium, antithyroid medication). US will show an enlarged thyroid gland, which should be differentiated from other neck masses.<sup>1</sup> Other causes of diffuse enlargement of the thyroid in infants are acute bacterial and subacute thyroiditis, autoimmune thyroiditis (Hashimoto thyroiditis), Graves' disease and multinodular goiter.

Persistence of the thyroglossal duct is a congenital anomaly of the thyroid gland, which with the accumulation of fluid may present with cystic characteristics. Thyroglossal

cysts are usually located in the midline that connects the gland with the base of the tongue.<sup>3</sup>

Cysts of the thyroid gland are usually benign; they may be simple epithelial cysts, colloid cysts, or hemorrhagic cysts resulting from blunt neck trauma or a hemorrhagic adenoma. The latter present with sudden enlargement of the gland and, as they develop, become filled with debris, and septation suddenly and fluid-fluid levels may be observed. Cystic nodules grow slowly compared with solid nodules; tissue sampling may be needed to identify the type of cyst.

Thyroid adenoma is a benign lesion with slow growth, which may be iso- or hyperechoic to the normal thyroid gland, and it is surrounded by a thin halo. It may enlarge suddenly in the case of spontaneous bleeding. Cystic changes, calcification and a peripheral vascular rim are some of the additional US features that may be observed.

All thyroid nodules must be measured in their transverse, longitudinal and antero-posterior diameter by calipers placed at the outer rim of the halo, which in the case of malignancy is thicker than 1–2 mm. Malignant nodules may not increase in size for many years, which means that the thyroid gland size may not be increased. On the other hand, very rapid growth of a thyroid nodule (>10–15 mm) may raise the suspicion of malignancy, including thyroid lymphoma, medullary carcinoma and anaplastic thyroid carcinoma.<sup>8,9</sup> Although nodule size is an important sonographic criterion, it does not definitively determine whether a nodule is benign or malignant, due to overlapping of the US features; biopsy is required to differentiate between benign and malignant thyroid nodules.

## ΠΕΡΙΛΗΨΗ

### Υπερηχογραφική εκτίμηση του θυρεοειδούς αδένου σε παιδιατρικούς ασθενείς

Θ.Ν. ΣΠΥΡΙΔΟΠΟΥΛΟΣ,<sup>1</sup> Α. ΠΑΠΑΪΩΑΝΝΟΥ<sup>2</sup>

<sup>1</sup>EchoHealth Ιατρείο Υπερήχων Παιδών και Ενηλίκων,

Αθήνα, <sup>2</sup>Β' Εργαστήριο Ακτινολογίας, Γενικό

Πανεπιστημιακό Νοσοκομείο «Αττικόν», Αθήνα

Αρχεία Ελληνικής Ιατρικής 2017, 34(2):264–266

Η υπερηχοτομογραφία διαδραματίζει σημαντικό ρόλο στην αξιολόγηση των δομών των μαλακών μορίων του τραχήλου, μεταξύ των οποίων και του θυρεοειδούς αδένου. Η υπερηχοτομογραφία αποτελεί εξέταση εκλογής για την εκτίμηση του μεγέθους και την αξιολόγηση της σύστασης και της αγγείωσης του παρεγχύματος του θυρεοειδούς αδένου. Οι

υπέρηχοι αποτελούν την απεικονιστική μέθοδο εκλογής για διάγνωση και επανέλεγχο εστιακών αλλοιώσεων του θυρεοειδούς σε παιδιατρικούς ασθενείς.

.....  
**Λέξεις ευρητηρίου:** Διαταραχές θυρεοειδούς, Θυρεοειδής αδένας, Όζοι, Παιδιά, Υπερηχογραφία

## References

1. PERRY RJ, HOLLMAN AS, WOOD AM, DONALDSON MD. Ultrasound of the thyroid gland in the newborn: Normative data. *Arch Dis Child Fetal Neonatal Ed* 2002, 87:F209–F211
2. GOLDIS M, WALDMAN L, MARGINEAN O, ROSENBERG HK, RAPAPORT R. Thyroid imaging in infants. *Endocrinol Metab Clin North Am* 2016, 45:255–266
3. BABCOCK DS. Thyroid disease in the pediatric patient: Emphasizing imaging with sonography. *Pediatr Radiol* 2006, 36:299–308
4. GHERVAN C. Thyroid and parathyroid ultrasound. *Med Ultrason* 2011, 13:80–84
5. VADE A, GOTTSCHALK ME, YETTER EM, SUBBIAH P. Sonographic measurements of the neonatal thyroid gland. *J Ultrasound Med* 1997, 16:395–399
6. LYSHCHIK A, DROZD V, DEMIDCHIK Y, REINERS C. Diagnosis of thyroid cancer in children: Value of gray-scale and power Doppler US. *Radiology* 2005, 235:604–613
7. ANDRIOLI M, CARZANIGA C, PERSANI L. Standardized ultrasound report for thyroid nodules: The endocrinologist's viewpoint. *Eur Thyroid J* 2013, 2:37–48

### Corresponding author:

T.N. Spyridopoulos, EchoHealth Pediatric and Adult Ultrasound Clinic, 56 Spyrou Merkouri street, GR-116 34 Athens, Greece  
 e-mail: t.spyridopoulos@echohealth.gr

.....