

CASE REPORT ΕΝΔΙΑΦΕΡΟΥΣΑ ΠΕΡΙΠΤΩΣΗ

Case presentation of a patient with left renal vein (nutcracker) syndrome

Nutcracker syndrome (NCS) is a vascular compression disease involving the compression of the left renal vein between the superior mesentery artery (SMA) and the aorta. The case is presented of a 33-year-old female patient with a 10-year history of hypertension and abdominal pain in whom NCS was diagnosed.

The left renal vein syndrome or nutcracker syndrome (NCS) is a rare anatomic-pathological condition. It can be diagnosed by imaging techniques in cases where NCS is suspected. Although the pathophysiology is unclear, recent studies show that the renal vein becomes compressed because of abnormal branching of the superior mesenteric artery (SMA) from the aorta.¹

NCS is the constriction of the left renal vein between the aorta and the SMA, or the constriction of the circumferential renal vein between the aorta and the vertebra in the retroaortic region, with the development of symptoms

associated with the increase in pressure in the part of the vein behind the compression. The most common clinical signs are hematuria, abdominal pain and hypertension.² This case report of a young female patient with laboratory and imaging findings is discussed because NCS is one of the rare causes which should be considered in the evaluation of hypertension.

CASE PRESENTATION

A 33-year-old female patient had been examined in another

ARCHIVES OF HELLENIC MEDICINE 2017, 34(2):250–252
ΑΡΧΕΙΑ ΕΛΛΗΝΙΚΗΣ ΙΑΤΡΙΚΗΣ 2017, 34(2):250–252

F. Gokosmanoglu,¹
C. Varim,²
H. Ergenc,²
G. Baycelebi,⁴
P. Varim,³
R. Colak,⁵
M.H. Atmaca⁵

¹Department of Endocrinology, Sakarya University Training and Research Hospital, Sakarya

²Department of Internal Medicine, Sakarya University Training and Research Hospital, Sakarya

³Department of Cardiology, Sakarya University Training and Research Hospital, Sakarya

⁴Department of Internal Medicine, Ordu Unye State Hospital, Ordu

⁵Department of Endocrinology, Ondokuz Mayıs University Medicine Faculty, Samsun, Turkey

Ασθενής με σύνδρομο
αριστερής νεφρικής φλέβας

Περίληψη στο τέλος του άρθρου

Key words

Abdominal pain
Hypertension
Left renal vein syndrome
Nutcracker syndrome

Submitted 21.5.2016

Accepted 30.5.2016

centre with complaints of intermittent left abdominal pain and hypertension for about 10 years, the etiology of which had not been identified at that time. On continuation of her complaints, the patient was admitted to our hospital for investigation. Physical examination showed that her general condition was good, apart from the arterial blood pressure (BP), which was 160/90 mmHg, the pulse was 78 beats/min, and there was no other abnormality.

Laboratory examination revealed: Blood glucose 85 mg/dL, creatinine 0.83 mg/dL, potassium 5.5 mEq/L, sodium 144 mEq/L, calcium 9.3 mg/dL, and urine protein 15 mg/dL (normal range 0–25), with erythrocytes 4/HPF (0–4). On duplex ultrasonography (US) the renal vascular structures appeared normal. Plasma aldosterone (PA) and plasma renin activity (PRA) were measured, because the cause of hypertension in a young patient may be aldosteronoma: PA 65 ng/dL (normal range 0–15), PRA 0.1 ng/mL/s (normal range 0.1–3.0), PA/PRA 650 ng/mL/s, and PA 52 ng/mL after the saline suppression test. These values were consistent with primary hyperaldosteronism. Upper abdominal computed tomography (CT), CT angiography and 3D CT scan were performed to view the adrenal glands and vascular structures. On CT the left renal vein was observed to be thinned at the level where it was constricted between the vertebral body and aorta (fig. 1). Venous angiography was performed to delineate the lesion identified by adrenal venous sampling and CT. This showed that the left renal vein was constricted between the aorta and the SMA, with dilation distal to the obstructed venous segment (fig. 2). Lateralization did not occur in adrenal venous sampling. Hypertension occurs in NCS due to an increase in renin and aldosterone, but in this case as hyporeninemic hyperaldosteronism was found, primary hyperaldosteronism and NCS were considered, and the patient was referred to the vascular surgery and urology clinics. Transposition of the left renal vein and a bypass operation were performed on the patient in the urology clinic. In the postoperative period the arterial BP was 110/70 mmHg, and laboratory examination showed PA 10 ng/dL, PRA 2 ng/mL/s and PA/PRA 5. This is the first time that hyporeninemic hyperaldosteronism with NCS has been reported

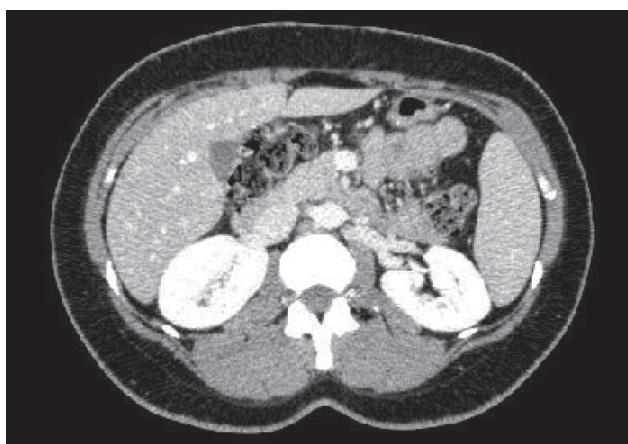


Figure 1. Computed tomography of the upper abdomen in a 33-year-old female with hypertension: The left renal vein is constricted between the vertebral body and the aorta (nutcracker syndrome).

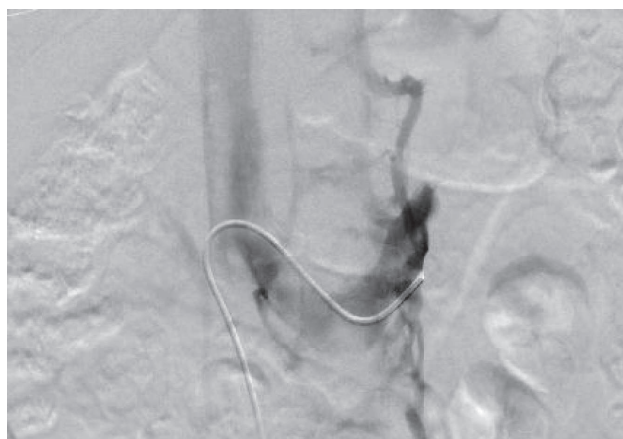

Figure 2. Left renal venous angiography in a 33-year-old female with nutcracker syndrome.

in the literature. In the postoperative period, the aldosterone and renin levels were normal and primary hyperaldosteronism was excluded. This situation was thought to be due to NCS.

DISCUSSION

In NCS an increase in pressure of the left renal vein occurs as a result of its entrapment at the meso-aortic angle. Reasons for entrapment include renal ptosis, abnormal division of the left renal vein at a high level, a narrow angle between the SMA and the aorta, a pancreatic mass, lymphadenomegaly and a lack of retroperitoneal adipose tissue.³ In this case, the left renal vein was trapped between the aorta and the SMA.

In a few cases with NCS, abdominal pain and gastrointestinal symptoms have been reported. Hematuria is a typical symptom occurring due to rupture of the thin-walled septum separating the urinary collecting system veins. NCS must be considered in the differential diagnosis of hematuria of unknown cause.⁴ Orthostatic proteinuria, vague flank pain and hypertension are other clinical symptoms in patients with NCS. This patient complained of left abdominal pain and hypertension with no other clinical or laboratory findings.

In NCS, hypertension is usually due to increased aldosterone secretion secondary to an increase in renin.⁵ In this case, there was suppression of renin due to primary aldosteronism. There was no lateralization in the increase in aldosterone in renal venous sampling, a finding that is consistent with primary hyperaldosteronism. In the postoperative period, however, renin and aldosterone levels were normal in the arterial blood. These findings suggested primary aldosteronism due to NCS.

In patients with a clinical illness compatible with NCS, imaging should be planned accordingly. Left renal venography, which is a traditional method providing an accurate diagnosis, is invasive. The non-invasive options are Color Doppler US, contrast-enhanced CT, CT angiography (CTA), magnetic resonance imaging (MRI) and MR angiography.²⁻⁶ NCS should be considered in patients with intermittent postprandial abdominal pain, left flank pain and hematuria, who should be evaluated with CT following careful physical examination. In the present case, the diagnosis of NCS was made with upper abdominal CT, plus CT angiography plus 3D CT scan, plus venous angiography.

This patient was referred to the vascular surgery and urology clinics for treatment. The treatment options include endovascular interventions, such as stenting of the left renal vein, and surgical procedures, such as medial nephropexy with excision of the renal varicosities, left renal vein bypass, left renal vein transposition among. Although there is no

consensus on this issue, open surgery and left renal vein transposition are less complicated and superior to other procedures because of producing less renal ischemia. The disadvantages of endovascular interventions are that they require prolonged anticoagulation and their long term complications and efficacy are unknown.⁷

In conclusion, the diagnosis of NCS must be considered in the presence of symptoms and signs such as microscopic and occasionally macroscopic hematuria, rarely orthostatic proteinuria, vague flank pain and hypertension. One of the most important factors which lead to diagnosis of the syndrome, defined as rare, namely hematuria, is not always detected in diagnostic examinations although in some studies, it was shown to be more common in patients with NCS, especially in children. The most important criterion in the diagnosis of NCS is hypertension, and this disease should always be considered in the investigation of young patients with hypertension.

ΠΕΡΙΛΗΨΗ

Ασθενής με σύνδρομο αριστερής νεφρικής φλέβας

F. GOKOSMANOGLU,¹ C. VARIM,² H. ERGENC,² G. BAYCELEBI,⁴ P. VARIM,³ R. COLAK,⁵ M.H. ATMACA⁵

¹Department of Endocrinology, Sakarya University Training and Research Hospital, Sakarya, ²Department of Internal Medicine, Sakarya University Training and Research Hospital, Sakarya, ³Department of Cardiology, Sakarya University Training and Research Hospital, Sakarya, ⁴Department of Internal Medicine, Ordu Unye State Hospital, Ordu, ⁵Department of Endocrinology, Ondokuz University Medicine Faculty, Samsun, Τουρκία

Αρχεία Ελληνικής Ιατρικής 2017, 34(2):250–252

Το σύνδρομο καρυοθραύστη (nutcracker) είναι η αγγειακή πίεση της αριστερής νεφρικής φλέβας μεταξύ της άνω μεσεντερίου αρτηρίας και της αορτής. Παρουσιάζεται μια περίπτωση ασθενούς με υπέρταση και κοιλιακά άλγη για μια περίοδο περίπου 10 ετών. Το σύνδρομο διαγνώστηκε με τις κατάλληλες εξετάσεις.

Λέξεις ευρητηρίου: Κοιλιακό άλγος, Σύνδρομο αριστερής νεφρικής φλέβας, Υπέρταση

References

1. CHEN YM, WANG IK, NG KK, HUANG CC. Nutcracker syndrome: An overlooked cause of hematuria. *Chang Gung Med J* 2002, 25:700–705
2. KURKLINSKY AK, ROOKE TW. Nutcracker phenomenon and nutcracker syndrome. *Mayo Clin Proc* 2010, 85:552–559
3. KURÇ E, BARUTCA H, KANYILMAZ M, SARGIN M, ŞAHİN S. Nutcracker syndrome. *Türk Gogus Kalp Dama* 2013, 21:146–150
4. TÜZÜN KH, ARSLAN C, DEŞER SB, ERSOY E, JUNUSBEKOV Y. Nutcracker syndrome: Case report. *Damar Cer Derg* 2012, 21:51–54
5. HOSOTANI Y, KIYOMOTO H, FUJIOKA H, TAKAHASHI N, KOHNO M. The nutcracker phenomenon accompanied by renin-dependent hypertension. *Am J Med* 2003, 114:617–618
6. OZEL A, TUFANER O, KAYA E, MALDUR V. US and MDCT diagnosis of a rare cause of haematuria in children: Posterior nutcracker syndrome. *J Ultrasound* 2011, 14:89–91
7. AHMED K, SAMPATH R, KHAN MS. Current trends in the diagnosis and management of renal nutcracker syndrome: a review. *Eur J Endovasc Surg* 2006, 31:410–416

Corresponding author:

C. Varim, Department of Internal Medicine, Sakarya University Training and Research Hospital, Sakarya, Turkey
e-mail: ceyhunvarim@sakarya.edu.tr