

CONTINUING MEDICAL EDUCATION ΣΥΝΕΧΙΖΟΜΕΝΗ ΙΑΤΡΙΚΗ ΕΚΠΑΙΔΕΥΣΗ

Vascular Diseases Quiz – Case 37

A 46-year-old female referred to our outpatient clinic by a general practitioner because of the sensation of a pulsatile mass in the neck. The patient reported some discomfort in the area of the mass without any other specific symptoms. Her past medical history was significant for hypothyroidism.

Physical examination revealed a non-compressible, painless mass in the left anterior triangle of the neck. Horizontal displacement of the mass was possible. Neither bruit nor thrill were present. There were no abnormal laboratory findings.

What is the diagnosis?

Comment

Carotid body tumors, also known as cervical paragangliomas or chemodectomas are rare. These tumors are sporadic in the large majority of cases, although in about 10% are familial. Their nature is benign; however they can have a malignant behavior in less than 5% of the cases. They are largely asymptomatic. High vascularity is a prominent characteristic of these tumors and consequently surgical resection may be problematic. Their blood supply derives predominantly from the external carotid artery. On physical examination, lateral displacement of the mass results in displacement of the carotid pulse (Fontaine's sign). Differential diagnosis includes carotid artery aneurysm, branchial cyst, low parotid tumors, benign or malignant nodal enlargement. Color Doppler imaging is accurate in the confirmation of clinical suspicion. Computed tomography angiography or magnetic resonance angiography are the most accurate diagnostic modalities. Once diagnosed, carotid body tumors must be surgically resected. In case of large tumors, completely or partially surrounding at least one of the carotid arteries, it is advisable to undergo preoperative selective embolization in order to reduce intraoperative bleeding and simplify surgical resection. In the present case, the tumor was resected without preoperative embolization because of its non-excessive diameter of 4 cm (fig. 1). No arterial repair was needed. Postoperative recovery was uneventful and the patient was discharged from hospital on the second postoperative day.

ARCHIVES OF HELLENIC MEDICINE 2016, 33(6):850
ΑΡΧΕΙΑ ΕΛΛΗΝΙΚΗΣ ΙΑΤΡΙΚΗΣ 2016, 33(6):850

G. Galanopoulos,^{1,2}
V. Papavassiliou¹

¹Department of Vascular Surgery,
"Sismanogleio" General Hospital, Athens
²Department of Pharmacology, Medical
School, Athens, Greece

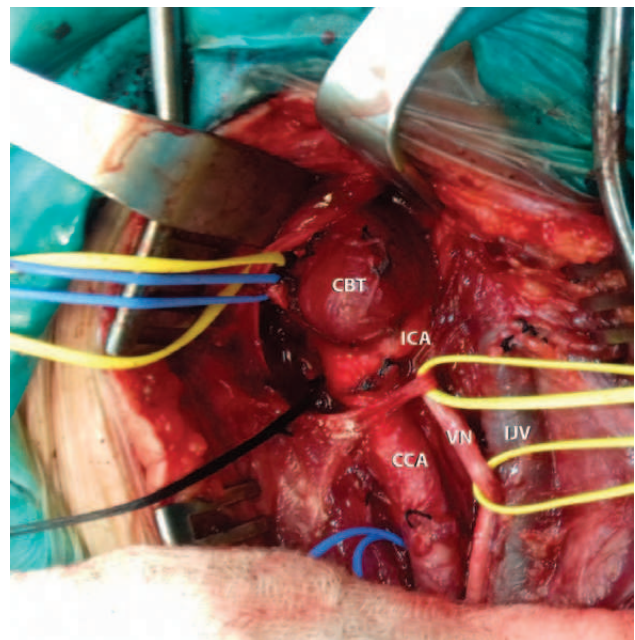


Figure 1. Intraoperative photo of carotid body tumor. CCA: Common carotid artery, ICA: Internal carotid artery, IJV: Internal jugular vein, VN: Vagus nerve, CBT: Carotid body tumor.

References

1. VAN DER BOGT KE, VRANCKEN PEETERS MP, VAN BAALEN JM, HAMMING JF. Resection of carotid body tumors: Results of an evolving surgical technique. *Ann Surg* 2008, 247:877–884

Corresponding author:

G. Galanopoulos, Department of Vascular Surgery, "Sismanogleio" General Hospital of Athens, 1 Sismanogleiou street, GR-151 26 Marousi, Greece
e-mail: georgiosgalanopoulos@yahoo.com

Diagnosis: Carotid body tumor