

CASE REPORT ΕΝΔΙΑΦΕΡΟΥΣΑ ΠΕΡΙΠΤΩΣΗ

A massive cystic splenic infarct in a patient with chronic lymphocytic leukemia Appearance on contrast-enhanced sonography

Massive splenic infarct, which is a rare clinical entity, is due to compromised blood flow in the spleen and occurs especially in the event of coagulopathy, hematological malignancy, endocarditis or other sources of embolization. The case is presented of a massive cystic splenic infarct in a patient with chronic lymphatic leukemia, in order to describe its contrast-enhanced sonographic features. Ultrasonography (US) confirmed the presence of a lesion measuring 13.5×10.6 cm, without the characteristics of a plain cyst, as it was hypoechoic but had well-defined borders within which there was amorphous material. The Doppler appearance showed no vascularization. After intravenous administration of contrast medium, the splenic parenchyma was enhanced in a homogenous manner, but the lesion remained as on the original US, with no enhancement at any phase.

Massive splenic infarct is a rare clinical entity, due to compromised blood flow in the spleen. It occurs especially as a complication of coagulopathies, hematological malignancies, endocarditis or other sources of embolization.¹ The case is presented of a massive cystic splenic infarct in a patient with chronic lymphocytic leukemia (CLL), in order to describe its contrast-enhanced sonographic features.

CASE PRESENTATION

A 71-year-old male patient was admitted to the hospital for investigation of a fever of 38.6 °C of 3 days' duration. His medical history included CLL, diagnosed 5 years earlier, and diabetes mellitus, hypertension and ischemic heart disease two years earlier.

Because of pain in the left upper quadrant of the abdomen with mild tenderness on palpation of the spleen, the patient underwent an abdominal computed tomography (CT), which revealed that the spleen was 22 cm in diameter, with a large hypodense lesion

measuring 13.5×10.6 cm with septae, compatible with splenic infarct (fig. 1). Hepatomegaly and abdominal lymphadenopathy were also noted, as had been detected two months previously, on re-examination for CLL in the hematology department. At that time, no splenic infarct was present. Abdominal CT performed at the onset of the fever in another hospital showed a lesion thought to be a splenic abscess.

Two days after the second abdominal CT, and because of the discrepancy between the two CTs, the patient underwent contrast-enhanced sonography of the spleen for further evaluation of the splenic lesion. The basic ultrasound (US) confirmed the splenomegaly and a hypoechoic lesion measuring 13.5×10.6 cm. Following intravenous administration of the contrast agent sulfur exafluoride microbubbles (SonoVue, Bracco), the splenic parenchyma showed homogenous enhancement, while the lesion remained without any enhancement (fig. 2A). With the use of the intravenous contrast agent, this lesion appeared wedge-shaped and well defined, but with no enhancing borders that would be characteristic of a splenic abscess. The absence of enhancement

ARCHIVES OF HELLENIC MEDICINE 2016, 33(6):831–833
ΑΡΧΕΙΑ ΕΛΛΗΝΙΚΗΣ ΙΑΤΡΙΚΗΣ 2016, 33(6):831–833

N.G. Vallianou,¹
E. Geladari,¹
K. Trigkidis,¹
T. Vagdatlis,²
E. Kokkinakis,¹
E. Antypa²

¹First Department of Internal Medicine,
"Evangelismos" General Hospital, Athens

²Department of Radiology,
"Evangelismos" General Hospital,
Athens, Greece

Μαζικό έμφρακτο σπληνός σε ασθενή με χρόνια λεμφογενή λευχαιμία: Υπερηχογραφική εικόνα μετά τη χορήγηση σκιαγραφικού μέσου

Περίληψη στο τέλος του άρθρου

Key words

Contrast-enhanced appearance
Massive splenic infarct
Ultrasonography

Submitted 7.2.2016

Accepted 15.2.2016

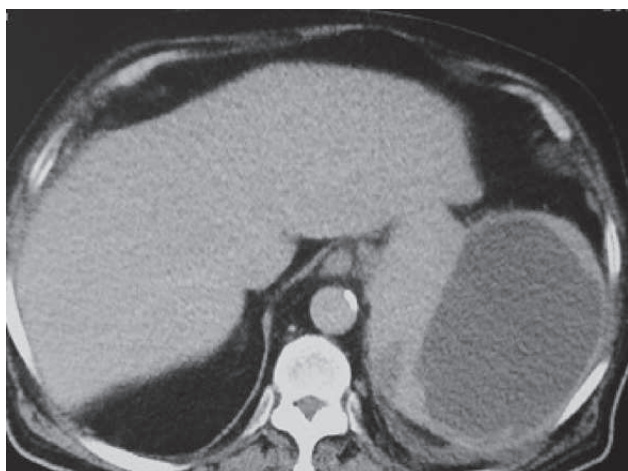


Figure 1. Abdominal computed tomography in a 71-year-old male depicting a massive splenic infarct 13.5×10.6 cm with septae.

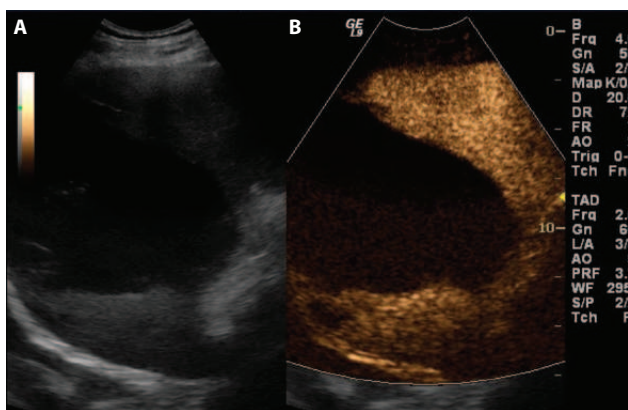


Figure 2. Contrast enhanced sonography of the spleen in a 71-year-old male. The basic sonography (A) confirmed splenomegaly with the presence of a lesion 13.5×10.6 cm, without the characteristics of a plain cyst, as it was more hypoechoic, with amorphous material within the lesion and with well-defined borders. The Doppler appearance showed no vascularization. After intravenous administration of contrast agent (B), while the splenic parenchyma was enhanced in a homogenous manner, this lesion remained without any enhancement at any phase of the contrast-enhanced sonography.

of the lesion after the administration of the contrast agent, along with the presence of amorphous material were compatible with a cystic splenic infarct with septae (fig. 2B).

The patient remained afebrile after the first two days of hospitalization. Blood cultures and evaluation for thrombophilia were negative. The splenic infarct was attributed to his underlying CLL, for which he had received no treatment. Splenomegaly due to CLL accounted for the splenic infarcts, which appeared to be responsible for the patient's fever.

DISCUSSION

Splenomegaly itself can account for the occurrence of splenic infarcts.¹ Patients with infectious mononucleosis, malaria and leishmaniasis may develop splenic infarcts, as well as patients with myelohyperplastic syndromes.²⁻⁴

Contrast-enhanced sonography is of great diagnostic value in various clinical situations for the differential diagnosis of splenomegaly, splenic infarcts, abscesses, tumors and injuries, functional asplenia and accessory spleen.⁵⁻⁷ It is noteworthy that Görg and colleagues, in their study of patients with pain in the left upper quadrant and splenic inhomogeneity, reported that contrast-enhanced sonography enabled visualization of splenic abnormalities in more than 50% of the patients; in this group, splenic infarction was the most common diagnosis.⁵ In the case presented here, contrast-enhanced sonography confirmed the findings of the abdominal CT performed in our hospital, and the patient did not have to undergo surgical intervention for a probable splenic abscess. The patient remains well 3 months after his hospitalization.

In conclusion, contrast-enhanced sonography may be a very useful tool in identifying splenic infarction, especially massive cystic infarcts as in this patient.

To our knowledge, this is the first report of massive cystic splenic infarct depicted by contrast-enhanced sonography.

ΠΕΡΙΛΗΨΗ

Μαζικό έμφρακτο σπληνός σε ασθενή με χρόνια λεμφογενή λευχαιμία: Υπερηχογραφική εικόνα μετά τη χορήγηση σκιαγραφικού μέσου

N. ΒΑΛΛΙΑΝΟΥ,¹ Ε. ΓΕΛΑΔΑΡΗ,¹ Κ. ΤΡΙΓΚΙΔΗΣ,¹ Θ. ΒΑΓΔΑΤΛΗΣ,² Ε. ΚΟΚΚΙΝΑΚΗΣ,¹ Ε. ΑΝΤΥΠΑ²
¹Α΄ Παθολογική Κλινική, Γενικό Νοσοκομείο Αθηνών «Ο Ευαγγελισμός», Αθήνα, ²Ακτινολογικό Τμήμα,
Γενικό Νοσοκομείο Αθηνών «Ο Ευαγγελισμός», Αθήνα

Αρχεία Ελληνικής Ιατρικής 2016, 33(6):831-833

Τα μαζικά σπληνικά έμφρακτα είναι σπάνιες κλινικές οντότητες, που οφείλονται σε διαταραχή της ροής του αίματος στον σπλήνα, ειδικότερα σε καταστάσεις υπερπηκτικότητας, αιματολογικές κακοήθειες, ενδοκαρδίτιδα ή σε πε-

ριπτώσεις που άλλες πηγές εμβόλων είναι παρούσες. Στην εν λόγω περίπτωση, παρουσιάζεται ασθενής με μαζικό, κυστικό έμφρακτο σπληνός σε έδαφος χρόνιας λεμφογενούς λευχαιμίας, προκειμένου να περιγραφούν τα ιδιαίτερα υπερηχογραφικά του ευρήματα, σε υπερηχογράφημα με χορήγηση σκιαγραφικού μέσου. Το υπερηχογράφημα επιβεβαίωσε την ύπαρξη βλάβης με διαστάσεις 13,5×10,6 cm, χωρίς όμως τα χαρακτηριστικά απλής κύστης, αφού ήταν πιο υποηχοϊκή με άμορφο υλικό εντός αυτής και με σαφώς αφοριζόμενα όρια. Στο υπερηχογράφημα Doppler δεν εμφανίστηκε αγγείωση. Μετά την ενδοφλέβια χορήγηση σκιαγραφικού μέσου, ενώ το σπληνικό παρέγχυμα ενισχύθηκε με ομοιογενή τρόπο, η συγκεκριμένη βλάβη παρέμεινε ως είχε, χωρίς ενίσχυση σε καμιά φάση κατά τη χορήγηση ενδοφλέβιου σκιαγραφικού μέσου.

Λέξεις ευρητήριο: Μαζικό έμφρακτο σπληνός, Υπερηχογράφημα, Χορήγηση σκιαγραφικού μέσου

References

1. www.uptodate.com
2. GAVRIILAKI E, SABANIS N, PASCHOU E, GRIGORIADIS S, MAINOU M, GAITANAKI A ET AL. Splenic infarction as a rare complication of infectious mononucleosis due to Epstein-Barr virus infection in a patient with no significant comorbidity: Case report and review of the literature. *Scand J Infect Dis* 2013, 45:888–890
3. HWANG JH, LEE CS. Malaria-induced splenic infarction. *Am J Trop Med Hyg* 2014, 91:1094–1100
4. MAO G, YANG G, CHENG Y, ZEE CS, HUANG W, NI W ET AL. Multiple nodular lesions in spleen associated with visceral leishmaniasis: A case report of MRI-findings. *Medicine (Baltimore)* 2014, 93:e272
5. GÖRG C. The forgotten organ: Contrast enhanced sonography of the spleen. *Eur J Radiol* 2007, 64:189–201
6. VON HERBAY A, SCHICK D, HORGER M, GREGOR M. Low-MI-sonography with the contrast-agent SonoVue in the diagnosis of infarction of the spleen, kidney, liver and pancreas. *Ultraschall Med* 2006, 27:445–450
7. CATALANO O, SANDOMENICO F, MATARAZZO I, SIANI A. Contrast-enhanced sonography of the spleen. *AJR Am J Roentgenol* 2005, 184:1150–1156

Corresponding author:

N.G. Vallianou, 5 Pyramidon street, GR-190 05 Marathonas, Greece
e-mail: natalia.vallianou@hotmail.com