

CONTINUING MEDICAL EDUCATION ΣΥΝΕΧΙΖΟΜΕΝΗ ΙΑΤΡΙΚΗ ΕΚΠΑΙΔΕΥΣΗ

Emergency Pediatric Imaging Quiz – Case 1

A 7-year-old boy presented to the Emergency Department of our hospital with acute onset of left quadrant abdominal pain after falling from 1 meter height on a cement surface. The boy's X-rays were normal. FAST ultrasonography (US) exam (focused assessment with sonography in trauma, FAST) revealed large peritoneal fluid collection, relatively hyperechoic (blood) and spleen contusions and lacerations (figures 1, 2a, 2b). The patient had peritoneal irritation during US examination; however, he was hemodynamically stable, responsive to fluid and one unit of blood administration. He was transferred immediately, after referral by surgeons, to our Computed Tomography (CT) Department for emergency abdomen CT imaging. Non-enhanced (NECT) and contrast-enhanced CT (CECT) were performed; no contrast blush consistent with active bleeding was noticed; however, a large non-perfused portion of upper part along with lacerations of spleen and hemoperitoneum was observed (figures 3, 4). The patient was under continued close clinical monitoring and remained hemodynamically stable with conservative treatment. Splenectomy was avoided and the boy discharged in good clinical condition.

Comment

The spleen is the most frequently injured abdominal organ.

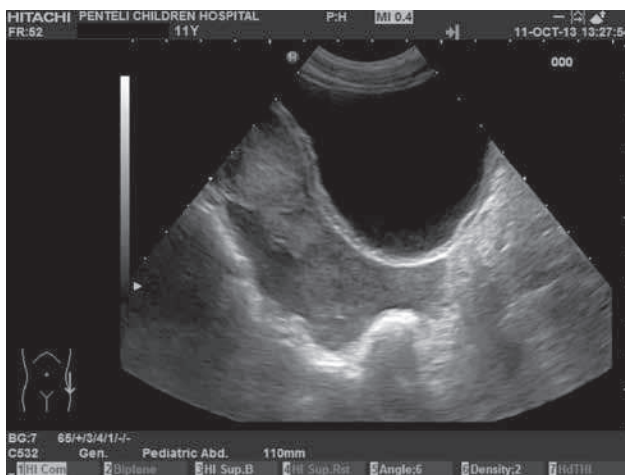

Figure 1. FAST (focused assessment with sonography in trauma) ultrasonography (US) (lower pelvis, sagittal view): Hyperechoic fluid collection, consistent with hemoperitoneum.

ARCHIVES OF HELLENIC MEDICINE 2014, 31(2):250–251
ΑΡΧΕΙΑ ΕΛΛΗΝΙΚΗΣ ΙΑΤΡΙΚΗΣ 2014, 31(2):250–251

T.N. Spyridopoulos,¹
A. Sakellaropoulos,¹
D. Bourikas,²
T. Dagla,¹
A. Stratigopoulou,¹
E. Anagnostaki,¹
N. Evlogias¹

¹Department of Radiology, Penteli
Children's Hospital, Palea Penteli

²Department of Pediatric Surgery,
Penteli Children's Hospital, Palea Penteli,
Greece

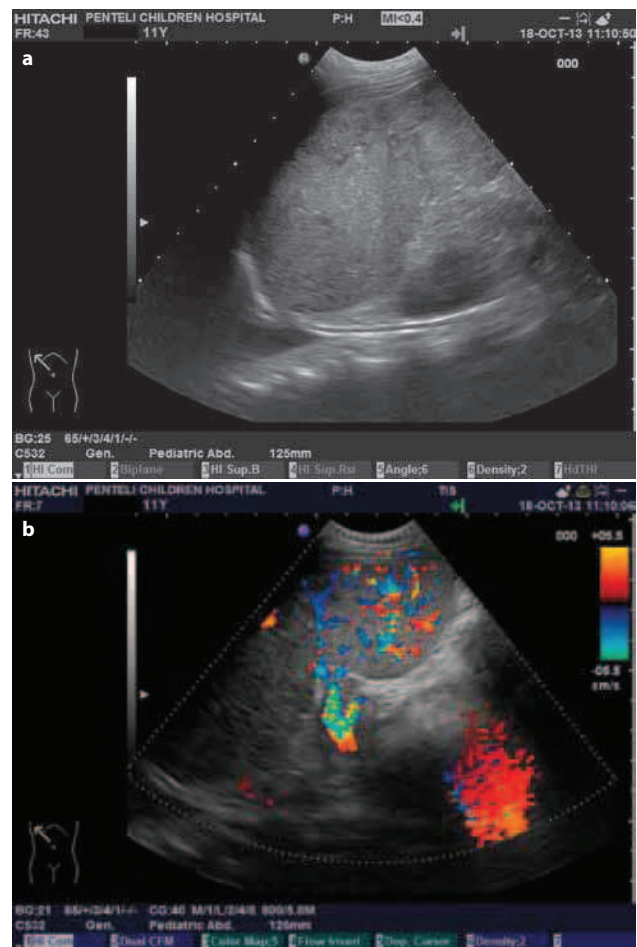


Figure 2a, b. (a) Gray scale oblique view of left upper quadrant: Focal relatively hypoechoic lesions in splenic parenchyma, consistent with lacerations. (b) Same view with color Doppler, reveals no perfusion of upper portion of spleen.

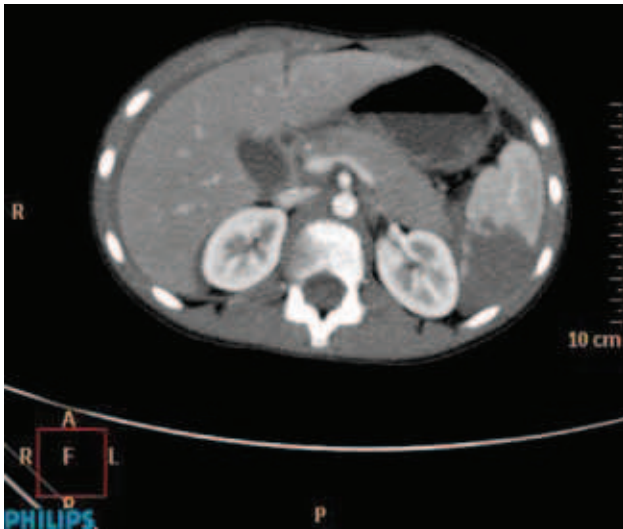

Figure 3. CECT of upper abdomen (axial view): Large portion of splenic parenchyma is hypoperfused; no contrast blush is noticed. Peritoneal fluid collection is observed (perihepatic space, Morrison recess and perisplenic space).

Delayed rupture of spleen may occur up to 10 days after trauma. Current management strives to avoid splenectomy. About 60% of patients with splenic injury do not have associated left lower rib fractures. The American Association for the Surgery of Trauma (AAST) had proposed a splenic CT injury grading scale (5 grades according to size of lacerations, subcapsular or central hematomas, splenic tissue maceration or devascularization), which is of limited clinical value since it does not predict the success rate of conservative management. On the other hand, the contrast extravasation has great impact of the patients' management; in the majority of such cases operative management is needed.

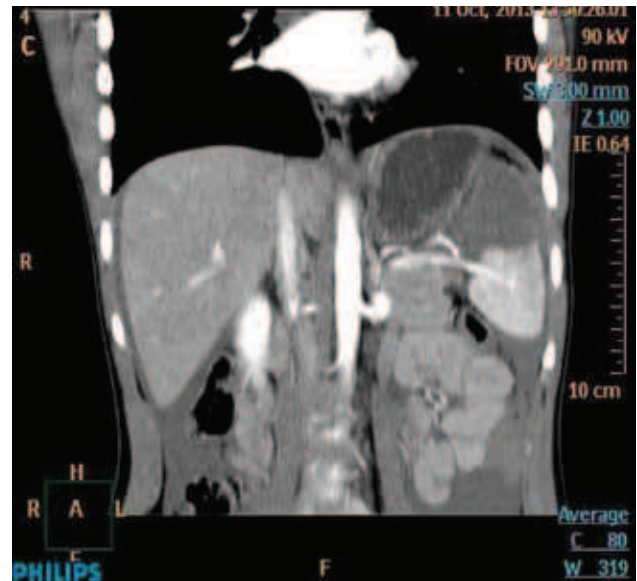


Figure 4. CECT of upper abdomen (coronal view): Note the hypoperfusion of upper pole of spleen and the normal enhancement of splenic artery.

References

- MARMERY H, SHANMUGANATHAN K, ALEXANDER MT, MIRVIS SE. Optimization of selection for nonoperative management of blunt splenic injury: Comparison of MDCT grading systems. *AJR Am J Roentgenol* 2007, 198:1421–1427

Corresponding author:

T.N. Spyridopoulos, Department of Radiology, Penteli Children's Hospital, Palea Penteli, Greece
e-mail: thspyrid@med.uoa.gr