

## CONTINUING MEDICAL EDUCATION ΣΥΝΕΧΙΖΟΜΕΝΗ ΙΑΤΡΙΚΗ ΕΚΠΑΙΔΕΥΣΗ

### Medical Imaging Quiz – Case 33

A 74-year-old man was referred for detailed examination of a change that had been noted on his chest roentgenography. He did not have any symptoms.

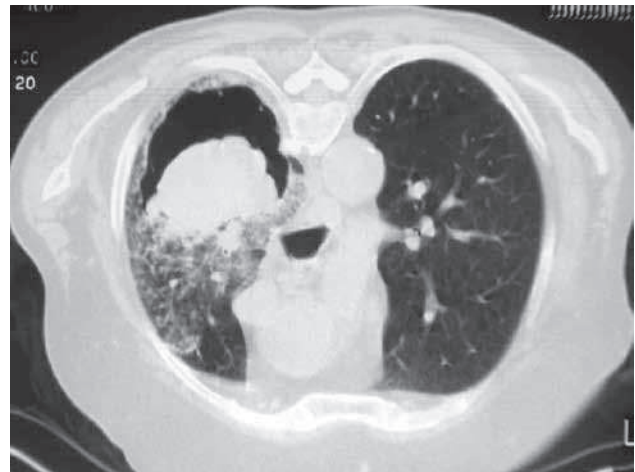The chest roentgenography was suggestive of non-homogenous opacity in right lower lobe. A CT (computed tomography) scan of the chest confirmed the presence of an oblong, dependent soft-tissue mass within the cavity (fig. 1). CT scan in the prone position showed that the mass moved within the cavity with the change in position (fig. 2).

The patient had history of pulmonary tuberculosis in the past for which he had taken adequate course of antitubercular treatment. At present, he had no history of fever, anorexia, and weight loss. Sputum for acid fast bacilli was negative. Routine hematological and biochemical investigations were normal. Bronchoscopy was performed which showed external compression of right lower lobe bronchus, with inflamed mucosa. Bronchial specimens were negative for malignant cells, and for pyogenic organisms but showed moderate growth of *Aspergillus fumigatus*. The patient was treated with amphotericin-B for three weeks. After that, he improved radiologically (fig. 3).

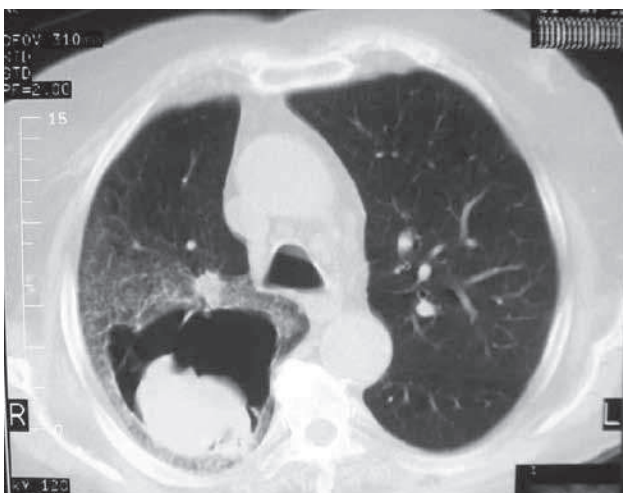
ARCHIVES OF HELLENIC MEDICINE 2013, 30(6):748–749  
ΑΡΧΕΙΑ ΕΛΛΗΝΙΚΗΣ ΙΑΤΡΙΚΗΣ 2013, 30(6):748–749

P. Galani,<sup>1</sup>  
L. Kosma,<sup>1</sup>  
A. Koundouraki,<sup>1</sup>  
K. Papagiannis,<sup>1</sup>  
K. Galanis,<sup>2</sup>  
S. Lafoyianni<sup>1</sup>

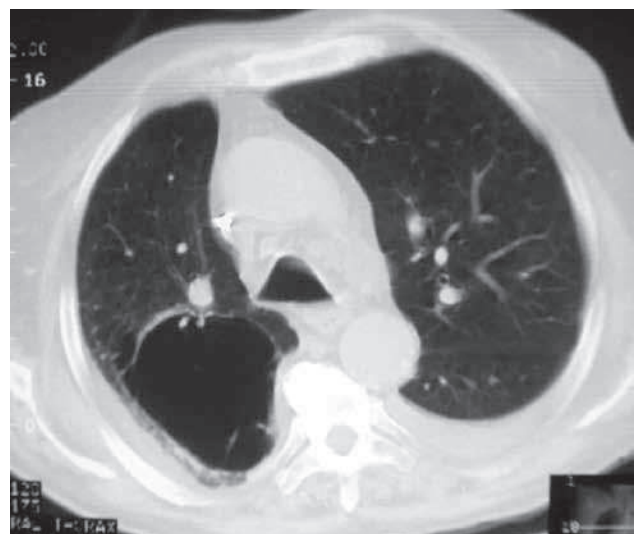
<sup>1</sup>Department of Computed Tomography,  
"A. Fleming" General Hospital, Athens,  
<sup>2</sup>Emergency Department, General  
Hospital of Chalkida, Chalkida, Greece



**Figure 2.** CT scan in the prone position shows that the mass moved within the cavity with the change in position.



**Figure 1.** CT thorax showing round mass within a cavity partially surrounded by a radiolucent crescent (crescent sign) in apical segment of right lower lobe.



**Figure 3.** CT scan after treatment.

### Comment

A pulmonary mycetoma is a round to oval-shaped mass of fungi situated within a cavity in the lung. Mycetomas have a predisposition to occur in preexisting pulmonary cavities. *Aspergillus fumigatus* is the most common saprophytic species of *Aspergillus*, leading to aspergilloma. A fungal ball is a term that describes a spatial configuration of saprophytic fungal overgrowth that occurs most frequently in the upper respiratory passages or the lungs. Damage to the bronchial tree and cavitary/cystic parenchymal disease predisposes to aspergilloma in some patients. In non-immunocompromised population, mycetomas have been reported to occur in 10–15% of patients with cavitating lung diseases. In regions where the incidence of tuberculosis is on decline, mycetomas are increasingly identified in advanced sarcoidosis, pneumoconiosis, bullous emphysema, bronchiectasis, lung abscess, neoplasms and pulmonary infarcts.

Radiologically, it presents as a solid, round or oval mass with soft-tissue opacity within a lung cavity. Typically, the mass is separated from the wall of the cavity by an airspace of variable size and shape, resulting in the “air crescent” sign. The aspergilloma usually moves when the patient changes position. CT is more reliable than chest radiograph in defining a fungus ball. A recent thickening of the wall of a pre-existing cavity and or pleural thickening may indicate early disease.

Patients with mycetoma are often asymptomatic. Amongst symptomatic, the most common symptoms include hemoptysis with

an incidence of around 80%, which is life-threatening in 30%. The natural history of patients affected is variable. Some aspergillomas are known to undergo spontaneous lyses. Many endorse surgical resections in view of high risk of unpredictable, life-threatening hemoptysis, which at times is recalcitrant to embolization procedures. Massive hemoptysis necessitates surgical intervention with resection of the affected lung or arterial embolization in the patient who is not suitable for surgery. The antifungal drugs –itraconazole, voriconazole or amphotericin B– are used, if complete surgical removal is not possible or if the *Aspergillus* infection has expanded beyond the aspergilloma.

### References

1. SINGHAL S. Pulmonary mycetoma. *Lung India* 2012, 29:81–82
2. FRANQUETT, MÜLLER NL, GIMÉNEZ A, GUEMBE P, DE LA TORRE J, BARGUÉ S. Spectrum of pulmonary aspergillosis: Histologic, clinical, and radiologic findings. *Radiographics* 2001, 21:825–837
3. SHAH R, VAIDEESWAR P, PANDIT SP. Pathology of pulmonary aspergillomas. *Indian J Pathol Microbiol* 2008, 51:342–345

Corresponding author:

P. Galani, Department of Computed Tomography, “A. Fleming” General Hospital, 14, 25th Martiou street, GR-151 27 Melissia, Greece  
e-mail: gioulagalani@yahoo.com