

CONTINUING MEDICAL EDUCATION ΣΥΝΕΧΙΖΟΜΕΝΗ ΙΑΤΡΙΚΗ ΕΚΠΑΙΔΕΥΣΗ

Hematology Quiz – Case 34

A 22-year-old shepherd was admitted to our Department because of severe abdominal pain and anemia. Colicky pain appeared two days before admission, accompanied by nausea and vomiting without either stool changes nor correlation with food intake. The patient also complained for weakness, fatigue and arthralgias. His past medical and family history were unremarkable.

On admission, physical examination revealed pallor and generalized abdominal tenderness without signs of peritonitis or ileus. Vital signs were normal. The spleen, liver and peripheral lymph nodes were not palpable. Neurologic examination revealed no abnormalities.

His hematological profile was as follows: White blood cells $11 \times 10^9/L$ (differential count: neutrophils 57%, lymphocytes 34%, monocytes 7% and eosinophils 2%), Hb 9.2 g/dL, Ht 27.8%, MCV 79 fL, MCH 26.4 pg, MCHC 33 g/dL, and platelets $236 \times 10^9/L$. The reticulocyte count was 4.2% and the erythrocyte sedimentation rate was 34 mm/1 hour. Peripheral blood smear morphology is shown in figure 1. The morphology of granulocytes and platelets was normal. Serum biochemistry was as follows: Urea 72 mg/dL, creatinine 2.1 mg/dL, sodium 138 mEq/L, potassium 5.4 mEq/L, SCOT 43 IU/L, SGPT 45 IU/L, γ GT 61 IU/L, alkaline phosphatase 122 IU/L, bilirubin 2.2 mg/dL (conjugated 0.9 mg/dL, unconjugated 1.3 mg/dL), LDH 340 IU/L (200–460 IU/L), haptoglobins 250 mg/L, ferritin 220 ng/mL, vitamin B₁₂ 418 pg/mL, and serum folate 6 ng/mL. The direct antiglobulin test (Coombs) was negative.

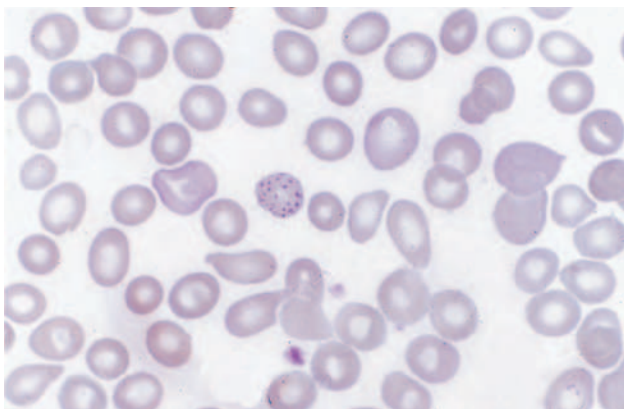


Figure 1

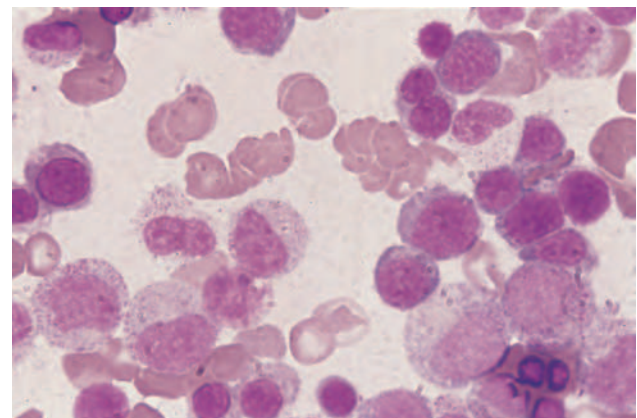


Figure 2

ARCHIVES OF HELLENIC MEDICINE 2013, 30(3):378–379
ΑΡΧΕΙΑ ΕΛΛΗΝΙΚΗΣ ΙΑΤΡΙΚΗΣ 2013, 30(3):378–379

L. Papageorgiou,
E. Koutsi,
K. Petevi,
G. Boutsikas,
A. Kanellopoulos,
G. Gainarou,
P. Flevari,
V. Telonis,
A. Bilalis,
A. Zannou,
A.E. Papakostas,
P. Tsafaridis,
E. Plata,
T.P. Vassilakopoulos,
M.K. Angelopoulou,
J. Meletis

Hematology Department and Bone Marrow Transplantation Unit, National and Kapodistrian University of Athens, School of Medicine, "Laikon" General Hospital, Athens, Greece

Thyroid function tests, chest X-rays, abdominal ultrasonography and electrocardiogram were also normal. The hemoglobin electrophoresis revealed no abnormalities. The osmotic fragility test was slightly abnormal (MCF 0.35 g/dL) while the autohemolysis test was within normal limits. Using a sephacryl gel microtyping system, no CD55 and or CD59 deficient red cell populations were detected in the peripheral blood. The bone marrow aspiration

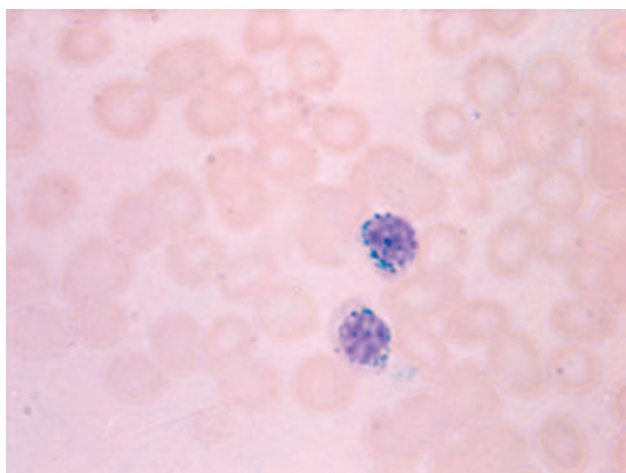


Figure 3

morphology and iron staining are shown in figures 2 and 3, respectively. Bone marrow conventional cytogenetic analysis was normal.

The urinary analysis for the detection of aminolevulinic acid showed an excretion of 14 mg/24 hours, while the levels of porphobilinogen were normal. Urinary coproporphyrin and uroporphyrin levels were also increased (500 µg/24 hours and 0.12 mg/24 hours, respectively). A blood test established the diagnosis and after the appropriate treatment patient's symptoms improved and hematological abnormalities were corrected.

Comment

Sideroblastic anemias are characterized by the presence of ringed sideroblasts in the bone marrow and decreased production of erythroid cells, because of heme synthesis perturbation.

The perturbation of erythropoiesis leads to the formation of ringed sideroblasts with the mitochondrial ferrum granules showing a circular distribution around the nucleus. In this situation, the ferrum granules are not ferrum-like as observed in the siderocytes and other kind of sideroblasts. Instead, they are ferrum-loaded mitochondria. In normal conditions, mitochondria have an active role in hemoglobin synthesis of erythroblasts and initially have a perinuclear situation while, when the cell is more mature, the nucleus becomes pyknotic and mitochondria goes into the periphery of the cytoplasm. This movement of the mitochondria is not present in sideroblastic anemia and thus the mitochondria are under a perinuclear nailing and are actually inactive because of their enzyme destruction by the insoluble ferric aggregations.

Patients with sideroblastic anemia have iron overload with high serum iron, transferrin saturation, and ferritin levels, as well as repletion of bone marrow iron stores. Abnormal heme synthesis is

the essential underlying disorder in sideroblastic anemia. Insufficient heme synthesis results to an excess of α and β hemoglobin chains (presence of two chain dimers). Diseases with abnormal heme synthesis (porphyria cutanea tarda, erythropoietic porphyria) have an increase of mitochondrial iron content and perhaps expresses similar disturbances with sideroblastic anemia. One of the most constant findings is an erythrocytic protoporphyrin excess.

Lead intoxication is a cause of sideroblastic anemia because of heme synthesis inhibition. Lead inhibits the activity of δ -aminolevulinic acid synthetase (conversion of δ -ALA to porphocholinogene), while it also acts on another enzyme of porphyrin synthesis. Lead is also related with iron metabolism, contacting the intracellular release in the place of ferrochelatase (decrease of iron supply in heme synthesis positions, absence of ringed sideroblasts), as well as with decrease of hemoglobin chains synthesis and with increase of red cell destruction (inhibition of ATPase and perturbation of 5-nucleotidase). The hematological findings in lead intoxication are heterogenous. Anemia is mild or moderate with mild hypochromia and microcytosis; reticulocytosis and sign of hemolysis are also present. A characteristic finding is a coarse basophilic stippling of red cells (ribosomal aggregations, abnormal RNA breakdown because of 5-nucleotidase insufficiency). In the bone marrow, erythroid hyperplasia is usually present, although bone marrow may be hypocellular, with rare presence of ringed sideroblasts. More specific findings include a decreased ALA synthetase activity, an increase of urine ALA content, as well as of erythrocytic protoporphyrin content that are present.

References

1. STAUDINGER KC, ROTH VS. Occupational lead poisoning. *Am Fam Physician* 1998, 57:719–726, 731–732
2. KWONG WT, FRIELLO P, SEMBA RD. Interactions between iron deficiency and lead poisoning: Epidemiology and pathogenesis. *Sci Total Environ* 2004, 330:21–37
3. McLINTOCK LA, FITZSIMONS EJ. Erythroblast iron metabolism in sideroblastic and sideropenic states. *Hematology* 2002, 7:189–195
4. HUNTER GA, FERREIRA GC. 5-aminolevulinic synthase: Catalysis of the first step of heme biosynthesis. *Cell Mol Biol (Noisy-le-grand)* 2009, 55:102–110
5. MELETIS J. *Atlas of Hematology*. 3rd ed. Nireas Publ Inc, Athens, 2009:164–168

Corresponding author:

J. Meletis, Hematology Department and Bone Marrow Transplantation Unit, National and Kapodistrian University of Athens, School of Medicine, "Laiko" General Hospital, Athens, Greece, tel.: +30 210 74 66 902, fax: +30 210 7456698
e-mail: imeletis@med.uoa.gr

Diagnosis: Lead poisoning