

CONTINUING MEDICAL EDUCATION ΣΥΝΕΧΙΖΟΜΕΝΗ ΙΑΤΡΙΚΗ ΕΚΠΑΙΔΕΥΣΗ

Medical Imaging Quiz – Case 25

During leisure time, a 5-year-old boy fell and then complained for left arm pain; so his parents brought him to the local health centre. He had an X-ray that showed a fractured lytic lesion of his proximal left humerus. After 3 weeks, he presented to our Computed Tomography Department for further investigation of the known bone lesion. The CT scan revealed a centered, solitary geographic lytic lesion of upper diaphysis of left humerus, with well-defined rim and no extension to the proximal epiphysis (fig. 1). The affected bone was expanded and fractured at the level of its maximum axial diameter, where also a periosteal reaction was noted, in the process of bone healing (fig. 2). At the lowest, gravity-dependent area of the lesion, a hyperdense (bone) fragment was also noticed (fig. 3). Along with patient's age and lesion's location, CT findings were strongly suggested the diagnosis.

Comment

Solitary bone cyst (SBC) is a fluid-filled lesion with fibrous lining, usually observed in children and adolescents. SBCs represent 3% of

all primary bone tumours and remain the most frequent cause of pathological fractures in long bones.

The classic appearance is a centrally located, lytic, well-margined, slightly expansible bone diaphyseal lesion that may cause cortical thinning or endosteal scalloping. SBCs usually begin at the epiphyseal plate and grow into the bone shaft; however, they have been described in almost every part of the human skeleton. Of note, SBC is one of few lesions that most frequently, does not occur around the knees; almost half of them occur in the proximal humerus. The "fallen fragment sign" has been described and is considered a classic finding for SBC. It represents a bony fragment of the thinned fractured cortical bone lying on the floor of the cystic lesion, indicating the presence of a fluid cavity rather than a solid material. This

ARCHIVES OF HELLENIC MEDICINE 2012, 29(3):387–388
ΑΡΧΕΙΑ ΕΛΛΗΝΙΚΗΣ ΙΑΤΡΙΚΗΣ 2012, 29(3):387–388

T.N. Spyridopoulos,¹
A. Stratigopoulou,¹
I. Papadopoulos,¹
I. Hager,²
N. Evlogias¹

¹Department of Radiology,
²Orthopedic Clinic, Penteli Children's
Hospital, Athens, Greece

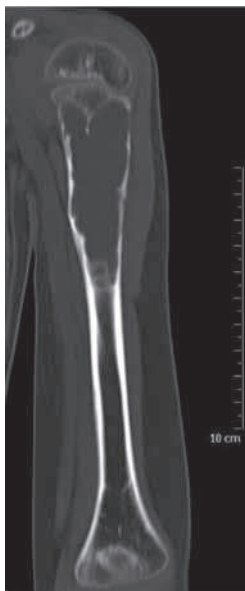

Figure 1. Coronal view of left humerus bone. A solitary, lytic, well-defined lesion is noticed in upper diaphysis. The affected bone is expanded, the cortex is thinned and endosteal scalloping is also observed.

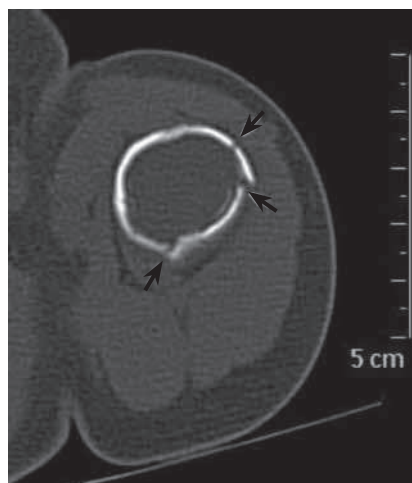


Figure 2. Axial view of left humerus, at the level of lesion's maximum diameter. Multiple fractures are observed (green arrows); periosteal reaction in the process of bone healing is also noticed (red arrow).

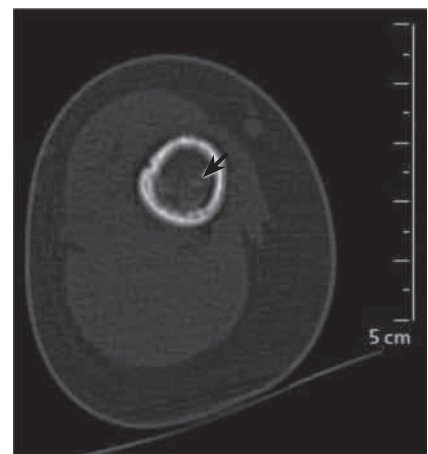


Figure 3. Axial view of left humerus, at the lowest, gravity-dependent level of lesion; hyperdense bony fragments are observed (green arrow).

sign aids the radiological differential diagnosis with other common lesion with similar imaging features (e.g. aneurysmal bone cyst).

Clinical manifestations of SBCs vary: It may be asymptomatic or present with pain and restriction in proximal joint movement, in case of a pathological fracture, especially in case that marked cortical thinning occurs.

References

1. BENSACHEL H, JEHANNO P, DESGRIPPES Y, PENNECOT GF. Solitary bone cyst: Controversies and treatment. *J Pediatr Orthop B* 1998, 7:257–261
2. HELMS CA. Benign cystic bone lesions. In: *Fundamentals of diagnostic radiology*. 3rd ed. Lippincott Williams & Wilkins, Philadelphia, 2007
3. REYNOLDS J. The “fallen fragment sign” in the diagnosis of unicameral bone cysts. *Radiology* 1969, 92:949–953

Corresponding author:

T.N. Spyridopoulos, Department of Radiology, Penteli Children's Hospital, Athens, Greece, Tel.: +30 2132 052 569
e-mail: thspyrid@med.uoa.gr