

ORIGINAL PAPER
ΕΡΕΥΝΗΤΙΚΗ ΕΡΓΑΣΙΑ

Effects of thymectomy on autoimmunity, thrombotic embolic events and ectopic thymoma

OBJECTIVE The effects of thymectomy were studied in patients with thymoma. **METHOD** Investigation was made in 41 patients who underwent thymectomy, with particular emphasis on 26 cases of myasthenia gravis (MG), in comparison with 4 cases of thymic carcinoma. **RESULTS** Lymphocyte predominant thymoma was the most frequent histological type (44%). One patient with MG both and a thymoma composed of lymphocytes mixed with epithelial cells presented ectopic thymoma in the pleura and lung 6, 11 and 12 years after thymectomy, which displayed increased atypia, resembling that seen in a case of intra-tracheal thymic carcinoma. Among the 26 patients with MG, 23 (88%) were positive for anti-acetylcholine receptor (AChR) antibody (Ab). Fifteen (65%) MG cases had peak values of AChR Ab before thymectomy. One patient with MG had anti-cardiolipin- β_2 glycoprotein 1 (CL- β_2 GP1) Ab. Prolonged aPTT of 428–200.0 sec was observed in MG patients. Complications among the 26 patients with MG were hepatic vein thrombosis (HVT) in 6, portal vein thrombosis in 1 and ileus in 2 cases, occurring 5 days to 6 years after thymectomy. In addition, myocardial infarction, deep vein thrombosis after cerebral infarction and pulmonary embolism were each observed in 1 patient with MG. **CONCLUSIONS** Post-thymectomy HVT and ileus did not result in severe infarction. Autoimmunity was improved due to a decrease in AChR Ab observed 1 month post-thymectomy. Pleural and lung ectopic thymoma with gradually elevating atypia in one benign thymic thymoma were judged to be caused by aberrations rather than by metastases.

Thymoma patients are grouped into those with and those without myasthenia gravis (MG). MG patients with autoimmune disorders report proximal muscle weakness, especially in the ocular muscles, as the initial symptom. The failure of neuromuscular transmission is caused by autoantibodies which disrupt the neuromuscular junctions (NMJs). These autoantibodies include acetylcholine receptor (AChR) antibody (Ab) and muscle-specific tyrosine kinase (MuSK) Ab. Anti-AChR Ab and MuSK Ab are present in 80–90% and 30–40%, respectively, of patients with MG, although in one report, 5% of MG patients were negative for both the antibodies.¹ In 1999–2000, the treatment and outcome results of 470 Japanese patients with MG were reported as follows:² thymectomy was selected in 319 (68%) patients, with a mean age of 40.1 years; 403 (86%), 301 (64%), 44 (9%), and 70 (15%) patients were treated with a cholinesterase inhibitor, corticosteroids, immunosuppressants, and plasmapheresis, respectively.

Among 395 patients followed up for more than one year, 92 (34%) of the 273 thymectomized and 26 (21%) of the 122 non-thymectomized patients were in remission of MG symptoms.

In the present study, 41 Japanese patients who underwent thymectomy for thymoma were examined during 1996–2008. Among the 41 patients, MG signs were present in 26. Anti-AChR Ab was detected in 23 patients with MG and anti-cardiolipin- β_2 glycoprotein 1 (CL- β_2 GP1) Ab was detected in 1 patient with MG. In MG patients showing prolonged activated partial thromboplastin time (aPTT), thrombotic embolic events occurred with a high frequency, but resolved quickly without serious residual clinical signs. Ectopic thymoma was found in one case of benign thymic thymoma with repeated relapses and increasing atypia.

Clinical improvement of thymoma signs were observed following complete resection of thymoma. The mechanisms of the thrombotic events and the characteristics of ectopic

ARCHIVES OF HELLENIC MEDICINE 2009, 26(5):656–662
ΑΡΧΕΙΑ ΕΛΛΗΝΙΚΗΣ ΙΑΤΡΙΚΗΣ 2009, 26(5):656–662

T. Nakatsuji

*Department of Transfusion Cell Therapy,
Hamamatsu University School of
Medicine, Hamamatsu, Japan*

Η αποτελεσματικότητα της
θυμεκτομής στην αυτοανοσία, τα
θρομβοεμβολικά συμβάματα και
την εμφάνιση έκτοπου θυμώματος

Περίληψη στο τέλος του άρθρου

Key words

Anti-acetylcholine receptor antibody
Autoimmunity
Ectopic thymoma
Hepatic vein thrombosis
Ileus
Myasthenia gravis
Portal vein thrombosis
Thymectomy
Thymic carcinoma
Thymoma

*Submitted 25.12.2008
Accepted 25.1.2009*

thymoma were considered in this study.

MATERIAL AND METHOD

Patients

The study was conducted on 41 Japanese patients with thymoma and 4 Japanese patients with thymic carcinoma who were admitted to the Hospital of Hamamatsu University School of Medicine, Japan between 1996 and 2008. The four thymic carcinoma cases were added to the investigation of thymoma cases in order to compare epithelial cell malignancy and implanted ectopic thymoma. The thymectomies were performed by surgeons in the 1st Department of Surgery of the study hospital. A diagnosis of MG in 26 of the thymoma patients was based on clinical records. Patient age was defined as age on the day of thymectomy.

Histopathological examination and laboratory analyses

All thymic thymomas were examined histopathologically in the Department of Pathology of the study hospital. In this study, thymoma was regarded as a paraneoplastic tumor and classified into five types. Based on the pathological results, the thymomas were classified as epithelial cell predominant, mixed lympho-epithelial cells, lymphocyte predominant, thymolipoma, or atrophy. To confirm the presence of thymic cell antigens, immunohistochemical staining using the streptavidin biotin-peroxidase method was added to the microscopic analyses, performed in the Department of Pathology. Laboratory data were obtained from the Central Laboratory of the study hospital. Activated partial thromboplastin time (aPTT, normal range: 24.0–36.0 sec) and prothrombin time (PT, normal range: 10.0–13.0 sec) were measured by light scattering. Anti-AChR Ab was detected by immunoprecipitation (IP). AChR Ab binding to α -bungarotoxin was investigated (normal range: 0–0.2 nmol/L). Serum calcium (Ca) (normal range: 8.5–10.4 mg/dL) was measured by ortho-cresolphthalein complexone (OCPC), and anti-cardiolipin- β_2 glycoprotein I (CL- β_2 GPI) Ab (0.0–3.5 IU/mL) was measured by enzyme-linked immunosorbent assay (ELISA). IgG (870–1700 mg/dL) was measured by turbidimetric immunoassay (TIA), and intact parathyroid hormone levels (I-PTH) (13.9–78.5 pg/mL) were measured by electrochemiluminescent immunoassay (ECL-IA). Autoimmunity was also diagnosed on the basis of a positive result for anti-nuclear antibody (ANA), homogenous (homogeneous type), and speckled (discrete speckled type) (0–40 times), which were assessed by ELISA. All patients suspected of having an autoimmune disease other than MG underwent these tests. Creatine kinase (CK, normal range: 55–204 IU/L in men and 42–164 IU/L in women), alanine aminotransferase (ALT: 5–42 IU/L), aspartate aminotransferase (AST: 11–30 IU/L), γ -glutamyltransferase (γ -GTP: 12–73 IU/L in men and 10–29 IU/L in women), and lactate dehydrogenase (LDH: 115–208 IU/L), were measured by the JSCC enzyme method. The results of chest radiography, abdominal computed tomography (CT), and heart magnetic resonance

imaging (MRI) were obtained from the Department of Radiology of the study hospital.

RESULTS

Pathological findings

Table 1 shows the histopathological findings of the 41 thymoma patients thymectomized during 1996–2008. Among the 41 patients, 26 (63%) showed signs of MG. The most frequent histopathology type was lymphocyte predominant, which was observed in 18 cases (44%). The mixed lympho-epithelial type was observed in 12 cases (29%). The epithelial cell predominant type was noted in 5 (12%) cases of non-MG, but no patient with MG had epithelial cell predominant thymoma. Four patients with thymic atrophy and two with thymolipoma had MG. Immunohistochemical staining results showed that the epithelial tumor cells were positive for AE1/AE3, CK7, CK14, p63, and CD57 Abs. The immature T cells in thymoma were positive for CD3, CD5, TdT, CD1a, and CD99 Abs. Figure 1 shows the clinical course of a 31-year-old woman with MG and an aggravated epithelial cell malignancy of an ectopic thymoma. In this patient, aberrant thymomas were found in the pleura, lung, chest wall, and diaphragm in 2002, followed by a pleural recurrence in 2007 and pleural and right lung recurrence in 2008.

At her first thymectomy in 1996, the original thymic thymoma was well encapsulated and histopathological examination revealed proliferation of lymphocytes and epithelial polygonal-oval cells with few atypia in a mixed type thymoma. However, in 2002, 2007 and 2008, small-lobed nodules of ectopic thymoma were observed, composed of

Table 1. Histopathological classification of 41 thymectomized thymoma patients.

Thymus pathology	Clinical diagnosis of myasthenia gravis (MG)		
	MG (-) No	MG (+) No	Total No
Thymoma	15	26	41 (100%)
Type			
Epithelial cell predominant	5	0	5 (12.2%)
Mixed lympho-epithelial cells	4	8	12 (29.3%)
Lymphocyte predominant	6	12	18 (43.9%)
Thymolipoma	0	2	2 (4.9%)
Atrophy	0	4	4 (9.8%)

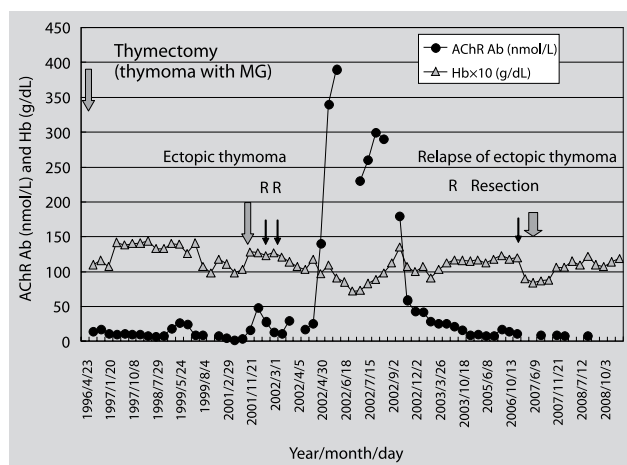


Figure 1. A case of MG with ectopic thymoma composed of atypical epithelial cells and small round lymphocytes with few atypia 6 years after thymectomy (case 1 in table 2). During the first detection of ectopic thymoma, elevated AChR Ab levels and aggravated anemia were detected. Clinical signs improved following the first surgical resection, but 5–6 years later, more atypical epithelial cells were observed in the recurrent tumors. Hb values $\times 10$ are shown in the figure.

atypical epithelial cells with nuclei of various sizes and small round lymphocytes with few atypia. The atypical epithelial cells had prominent nucleoli. The patient recovered once after the ectopic thymoma nodules were resected, but in 2008, 3 mushroom-like shaped tumors bordering on pleura were recognized by CT in the right lung where the recurrent pleural thymoma was resected in 2007. Figure 2 shows a part of the clinical course of a 52 year-old woman who underwent thymectomy for thymic carcinoma in 1993, at which time metastasis to the lung was observed. The thymic carcinoma recurred in the chest wall in 1997 and in the intra-bronchial spaces in 2000. She underwent intra-bronchial tumor resection several times. In December 2002, a bronchial tumor biopsy revealed oval to spindle epithelial cell nests, with greater atypia, and necrosis. In 2003, tumor cells displayed increased atypia. In October 2003, her prolonged aPTT normalized, but she died of dyspnea in December 2006. The morphological atypia of the tumor epithelial cells corresponded with the clinical changes. The case shown in figure 2 with thymic carcinoma metastasis showed similar histopathological changes to those of the case in figure 1 with ectopic thymoma. A thymic carcinoma in a 66 year-old male displayed irregular solid nests of tumor cells with hyperchromatic, round nuclei that had prominent nucleoli. The atypical epithelial cells were embedded in the dense collagenous stroma and were accompanied by sparse lymphoid components. The tumor cells displayed strong bcl-2 immunoreactivity. Of the 4 cases of thymic carcinoma, 2 (50%), including this case, stained positively for bcl-2 and p53 Abs. CAM5.2, AE1/

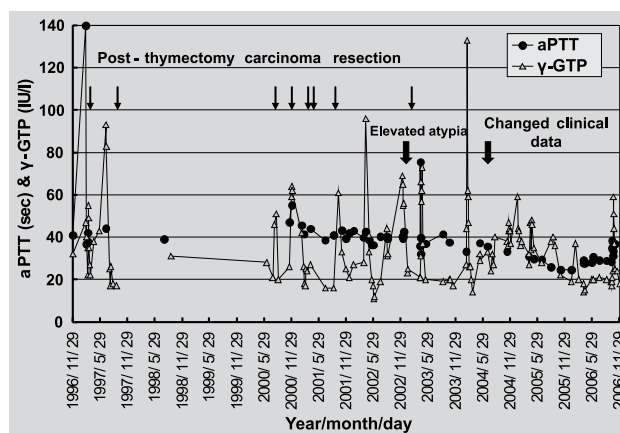


Figure 2. A case of thymic carcinoma without MG. Metastases had occurred already before thymectomy. Aggravated epithelial tumor cells were evident in an intra-bronchial recurrence 9 years after thymectomy. Together with histopathological atypia, the clinical signs of aPTT and γ -GTP were rather improved. However, malignant clinical signs had progressed and the patient died of dyspnea.

AE3, CK14, EMA, and CK7 Abs stained positively in thymic carcinoma cells derived from thymic epithelial cells. One patient without MG who had a lymphocyte predominant thymoma died of malignant melanoma (MM) about one year after thymectomy.

Autoimmunity in MG

AChR Ab was examined in all 26 MG patients, and was detected in 23 (88%) patients. Peak AChR Ab (nmol/L) varied from 1.8 to 12,000 (nmol/L) in these patients. Peak AChR Ab was measured before thymectomy in 15 (65%) of the 23 cases. Within the first month after thymectomy, 6 (26%) cases experienced their peak AChR Ab. In the exceptional case shown in figure 1, a peak AChR Ab of 390 nmol/L was noted in aberrant thymoma nodules approximately 6 years after thymectomy. One patient with MG had a peak AChR Ab 5 months after thymectomy, with no evidence of ectopic thymoma. One patient with MG (case 6 in table 2) who was negative for AChR Ab was thymectomized at the age of 66 years, because of thymic atrophy. She had proximal muscle disturbances, including ptosis, dysphagia and dysphonia. Low levels of urine creatinine, 428.9 ± 118.3 mg/day ($n=18$) (normal range: 1000–1500 mg/day), and serum CK, 39 ± 14 IU/L ($n=18$), were observed during the period immediately after thymectomy. Her clinical signs were consistent with MG. Case 5 in table 2 was positive for anti-CL- β_2 GPI Abs with systemic lupus erythematosus (SLE). Four (15%) MG patients were positive for ANA. The lowest IgG was 448 mg/dL in one man with MG, which triggered ileus (case 2 in table 2). At least 7 (27%) patients

Table 2. Laboratory findings in thymectomy (Tx) patients with hepatic vein thrombosis (HVT), portal vein thrombosis (PVT) and ileus.

Case no	Pre-thymectomy		Post-thymectomy				Event	Post-Tx Time
	aPTT	γ -GTP	aPTT	γ -GTP	ALT	CK		
1 ^{Fig 1}	NT ^a	NT	>200	501	158	14	HVT	6 Y
2	95.4	4	NT	34	10	2194	Ileus	1.36 Y
3 ^{Fig 3}	>200	38	30.0	765	96	33	HVT	1.3 M
4	35.6	12	27.2	60	133	28	HVT	5 D
5	84.2	14	34.2	871	686	42	HVT	0.5 M
6	34.1	9	26.8	599	112	20	HVT	3.8 M
			42.8	14	18	608	Ileus	3 Y
7 ^{Fig 4}	34.6	22	42.8	178	1050	22	PVT	1.1 Y
8	35.9	30	NT	206	182	61	HVT	2 M

^a Not tested; case 3: MI, case 4: IB, case 5: CI and deep vein thrombosis (DVT), Y: Year, M: Month, D: Day

with MG had IgG levels lower than the normal minimum of 870 mg/dL. Autoimmunity, which was related to thymoma, diminished or weakened along with signs of MG after thymectomy.

Thrombotic embolic events

Table 2 shows clinical data from the 8 thymectomized MG patients with thrombotic embolic events in the liver and intestine. In cases 1, 2, 3, 5, 6, and 7, a prolonged aPTT of 42.8 to 200 sec was observed. In practice, immediately after the time of thrombus formation the aPTT was longer than 200 sec, which got over reliable ranges. As PTH was within the normal range in cases 2 and 4, hypoparathyroidism was judged not to be present in any of the patients. In the HVT, a sharp peak in γ -GTP, which was produced by intra-hepatic bile ducts, was observed, accompanied by elevated ALT values, as shown in figure 3. Figure 3 shows the clinical course of case 3, who was thymectomized at the age of 57 years in June 2001, because of thymic atrophy. As he had angina pectoris, a coronary artery bypass (CAB) was combined with the thymectomy and he had mild HVT before thymectomy. Two days before his thymectomy, the aPTT was >200 sec with a PT of 14.1 sec, after which the γ -GTP spiked sharply twice. His Hb values dropped suddenly, from 14.3 g/dL to 12.3 g/dL, 10 days before thymectomy, and remained low until thymectomy. Nine days after thymectomy, the γ -GTP rose to 304 IU/L, and LDH to 487 IU/L. A second spike in γ -GTP (765 IU/L) was observed one month later with an ALT of 96 IU/L and LDH of 369 IU/L, as shown in table 2. He suffered acute myocardial infarction (AMI) in 2004 and heart failure with an elevated brain natriuretic peptide (BNP) (179 pg/mL) (normal range: 0–18.4 pg/mL) in 2007. At the time

of the AMI, a heart MRI strongly suggested posterior wall infarction with delayed enhancement. He had diabetes mellitus (DM) and the blood sugar (BS) reached 345 mg/dL with fluctuating waves of BS elevation, and continued to worsen from 2003. On one day, he had serum insulin levels of 23–65 μ U/mL (normal range: 5–19 μ U/mL). He was treated with aspirin (100 mg/day), warfarin potassium (1 mg/day), and insulin lispro 60 U/day. Supervening insulinoma was suspected. Case 4 suffered HVT peri-thymectomy, then one year and 5 months after thymectomy, severe intestinal bleeding (IB) occurred suddenly, without signs of ileus. She recovered after a 400 mL transfusion of red

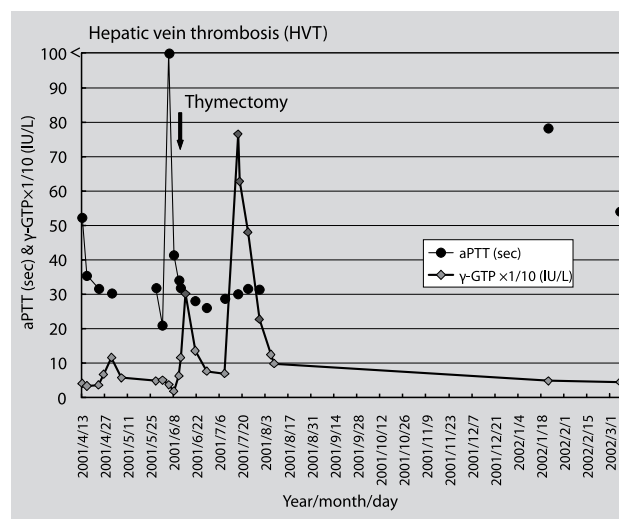


Figure 3. A case of MG with thymic atrophy. The patient had HVT, angina pectoris, AMI and gradually worsening DM, and was suspected of insulinoma (case 3 in table 2). HVT was indicated by prolonged aPTT and elevated γ -GTP. He had HVT with elevated γ -GTP before thymectomy, but peak γ -GTP was observed 1.3 months after thymectomy.

blood cells. The presence of hypocalcemia appeared to be related to the bleeding. Case 5 was thymectomized at the age of 28 years in September 2003. She had MG, SLE, and anti-phospholipid Ab syndrome. Her aPTT was >80 sec before thymectomy, with low plasminogen levels of 74–81% (normal range: 78–120%). Sixteen days after thymectomy, the liver enzymes peaked with an ALT of 686 IU/L, alkaline phosphatase (ALP) of 976 IU/L (normal range: 25–43 IU/L), γ -GTP of 871 IU/L, aPTT of 73 sec, and fibrin degradation product dimer (FDP-D) of 3.1 μ g/mL. All these pathological levels gradually normalized at the end of 2003. HVT was diagnosed 25 days after thymectomy, when the aPTT was >200 sec, with a fibrinogen (Fbg) level of 70 mg/dL, which indicated the formation of a new thrombus. Cerebral infarction (CI) was diagnosed with the signs of sensory disturbances on the left side of her body in June 2005. She was treated with 1.5 mg/day of warfarin potassium and 100 mg/day of aspirin from December 2006. She became pregnant and gave birth to a baby in June 2007 with the assistance of aspiration. As shown in figure 4, of case 7 in table 2 in portal vein thrombosis (PVT), bilirubin levels were elevated during the portal vein obstruction, with very high ALT values. Case 7 in table 2 was thymectomized at the age of 22 years because of a thymolipoma (fig. 4). She had AChR Ab of 1500 nmol/L 15 days after thymectomy. Approximately one year after thymectomy she presented with abdominal pain resembling a gallstone attack and acute hepatitis signs. Tests for infectious viral hepatitis A,

B, and C, cytomegalovirus (CMV), and Epstein-Barr virus (EBV) were all negative. Abdominal CT revealed a collapsed gallbladder with mild splenomegaly, but no signs of intra-hepatic obstruction. An elevated total bilirubin of 23.4 mg/dL with a delayed peak of indirect bilirubin of 7.3 mg/dL was observed, along with a prolonged aPTT of 42.8 sec and elevated ALT of 1,050 IU/L. The PVT resolved after approximately 2 months. According to ileus–intestinal perforation– events, a sharp peak in CK is observed, with normal liver enzyme levels, as shown in table 2. In addition to a sharp peak in CK, case 2 had an ileus attack, LDH of 314 IU/L, 16 months after thymectomy. Subsequently rectal adenocarcinoma was diagnosed in case 2 in 2005 and renal clear cell carcinoma in 2008. Case 6 in table 2 had levels of total protein (TP) as low as 4.2 mg/dL from the period immediately after thymectomy. From one week to two months after thymectomy, the liver enzymes spiked and fluctuated, indicating the presence of HVT. After the last HVT formation, serum TP levels returned to between 6 and 7 mg/dL, but septic shock with ileus occurred suddenly 3 years after thymectomy. White blood cell (WBC) counts were elevated to 37,800/ μ L, with a serum CK of 608 IU/L, and urine β_2 microglobulin (β_2 -m) of 20,784 μ g/L (normal range: 15–271 μ g/L). She (case 6) recovered from the septic shock and ileus 5 days later. During an attack of ileus, she had a transiently low level of serum Ca of 6.9 mg/dL. One patient –not shown in table 2– who had suffered a pulmonary embolism (PE) before thymectomy, developed another PE during the first month after thymectomy, but gradually recovered.

It is interesting to note that half of the patients with thymic atrophy (cases 3 and 6) and thymolipoma (case 7, with high AChR Ab) experienced thrombotic embolic events.

DISCUSSION

In this study, among 26 patients with MG, 23 (88%) were positive for anti-AChR Ab, and 9 had thrombotic embolic events. Neuronal nicotinic AChR (nAChR) has Ca^{2+} -permeable ligand-gated channels. Alpha 7 ($\alpha 7$)-nAChR is characterized by rapid desensitization and high permeability to Ca^{2+} . Although Ca^{2+} elevation is associated with $\alpha 7$ -nAChR activation, one patient with MG and lymphocyte predominant thymoma had a level of AChR Ab of 1,600–12,000 nmol/L. The condition continued for 7 years after thymectomy. Her AChR Ab was likely due to the high concentration of $\alpha 7$ -nAChR Ab. In this study, 9 severe cases of MG with thrombotic embolic events were investigated, with suspected antibody activity against Ca

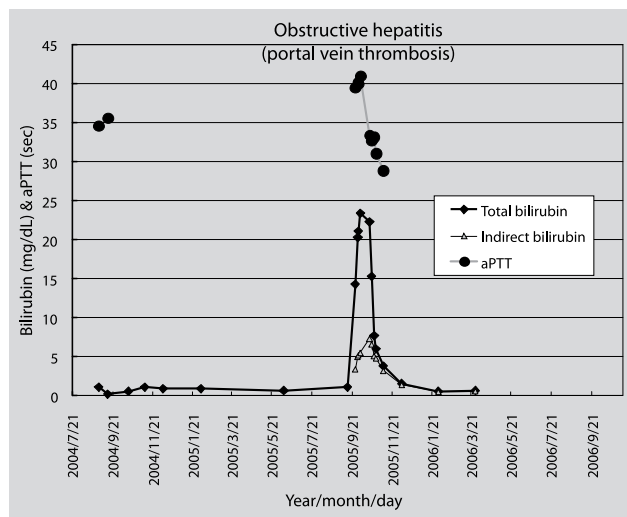


Figure 4. A case of MG with thymolipoma-type thymoma (case 7 in table 2). She had high levels of AChR Ab during, before and 15 days after thymectomy. PVT with acute hepatitis, which initially resembled a gallstone attack, was observed 1.1 years after thymectomy. Compared with HVT, she had abnormally high levels of total bilirubin and ALT. A prolonged aPTT was detected at PVT.

channels. In 1992, the ryanodine receptor (RyR) Ab was identified using western blot in 14 (47%) of 30 patients with MG and thymoma.⁴ RyR Ab was discovered in the serum of patients with severe thymoma MG or late-onset severe MG.⁵ Recently, one report indicated the presence of an autoantibody against the transient receptor- and store-operated Ca^{2+} influx channel, transient receptor potential canonical type-3 (TRPC3), which interacts with RyR1.⁶ In that study of 25 Japanese with MG, the author detected TRPC3 peptide Ab in 9 (36%) cases and RyR1 peptide Ab in 16 (64%) cases.⁶ Store-operated Ca^{2+} channels (SOCs) of hepatocytes, lymphocytes and mast cells have a high selectivity for Ca^{2+} .⁷ TRPC3 Ab interrupts Ca signaling pathways in the hepatocytes, lymphocytes and mast cells. As the number of patients with severe MG in this study was similar to those of the reported patients with the TRPC3 Ab, it was concluded that severe MG was caused by the presence of the TRPC3 Ab.⁶ About 60–65% of the patients in this study were believed to be positive for RyR1 Ab, because the RyR1 Ab had been found in 64% of a similar Japanese MG group.⁶ The cardiac and skeletal muscle RyR Ca^{2+} release channels contain thiols.⁸ The thiols of RyR are potential targets of endogenously produced reactive oxygen and nitrogen intermediates.⁸ RyR Ab might cause a loss of physiological RyR1 functions when patients with MG were exposed to reactive oxygen and nitrogen intermediates. Subsequently, cholestatic bile acids in intra-hepatic bile ducts, the sign of which was elevated levels of γ -GTP in this study, inhibit the hepatocyte SOCs through the functions of bile acid-induced stromal interaction molecule 1 (STIM1).⁹ When hepatocytes have severely inhibited SOCs, hepatocyte apoptosis is induced by interruption of Ca signaling pathways. After large amounts of Ca are released transiently from the cytoplasmic space, endoplasmic reticulum (ER) and cell mitochondria, coagulability might suddenly be activated. As long as patients with MG are not attacked by reactive oxygen or nitrogen intermediates, the TRPC3 and RyR Abs seem not to cause Ca release into the serum. As very prolonged aPTT, but not PT, is observed at the next stage of hypercoagulation, the intrinsic coagulation system, in which platelet factor 3, factor (F) XII, FXI, and FVIII are utilized, must play an important role in active coagulation. As plasminogen levels were low or under normal in the patients with severe MG, tissue plasminogen activator (t-PA) in the blood must be activated, resulting in fibrinolysis, but which was not main. Very prolonged aPTT of >200 sec was observed uniquely in HVT and there were no patients who developed severe embolism. PVT in the patient with thymolipoma was explained as follows:⁹ SOCs and STIM1 become targets for the actions of bile acids. Cholestatic bile acids in the extra-hepatic bile ducts inhibited the SOCs through bile-acid induced STIM1. Gall-

bladder SOCs were considered to be the primary origin of activated coagulation. As a conclusion, this study showed that bile ducts played an important role in HTV and PVT. Concerning intestinal troubles, intestinal lymph nodes were suspected to be targets for SOC dysfunction. In the men with MG who suffered AMI and heart failure in this study, in addition to RyR1 Ab, Ab against RyR2, which is not activated or S-nitrosylated directly by NO, might have been produced, leading to the patient's cardiac events.

One patient with MG and benign thymic thymoma developed aberrant thymoma with cancerous characteristics in the pleura, lung and diaphragm 6 years after thymectomy and the aberrant thymoma recurred with greater atypia 11 and 12 years after thymectomy. One thymic carcinoma of epithelial cells showed accelerated tumor atypia in a recurrence in the intra-bronchial space 9 years post-thymectomy. Pleural recurrence of thymoma, which was observed most frequently among recurrent thymomas 3–7 years after thymectomy, is best treated by radical resection of the tumor, which results in improved survival.^{10,11} Primary thymoma is found not only in thymic tissue, but also in the neck, trachea, thyroid, parathyroid, pericardium, heart, pleura, and lung.¹² Primary intrapulmonary thymoma is defined as a tumor below the visceral pleura or entirely circumscribed by lung parenchyma with histopathological features of thymoma, when a thymic lesion is not detected in the anterosuperior mediastinum. About 50% patients with primary intrapulmonary thymoma become tumor free after surgical resection, with 4% recurrence and 24% mortality. Ectopic thymoma is believed to be caused by embryologic displacement. When patients with MG have a thymic thymoma, it is difficult to decide whether ectopic thymomas are primary lesions or metastases. Even when thymic thymoma is present, there is a possibility that ectopic thymoma develops separately after thymectomy. For example, a thymic thymoma in this study was a well encapsulated, non-neoplastic tumor in 1996, but between 2002 and 2008, the pleura and lung aberrant thymoma which developed later was neoplastic. When ectopic thymomas displayed more pronounced tumor atypia than the benign primary thymomas after thymectomy, the ectopic thymomas could be another primary thymoma caused by embryonic displacement. Except for thymic carcinoma in the thymus, it could be decided that subsequent extra-thymic thymomas were aberrations.

ACKNOWLEDGEMENTS

The author thanks the physicians of the First Departments of Surgery and the Department of Pathology of Hamamatsu University Hospital, Japan for providing the data for this study.

ΠΕΡΙΛΗΨΗ

Η αποτελεσματικότητα της θυμεκτομής στην αυτοανοσία, τα θρομβοεμβολικά συμβάματα και την εμφάνιση έκτοπου θυμώματος

T. NAKATSUJI

Department of Transfusion Cell Therapy, Hamamatsu University School of Medicine, Hamamatsu, Japan

Αρχεία Ελληνικής Ιατρικής 2009, 26(5):656–662

ΣΚΟΠΟΣ Μελετήθηκαν τα αποτελέσματα της θυμεκτομής σε 41 ασθενείς με θύμωμα. **ΥΛΙΚΟ-ΜΕΘΟΔΟΣ** Δόθηκε μεγαλύτερη έμφαση σε 26 περιπτώσεις με βαριά μυασθένεια και έγινε σύγκριση με 4 περιπτώσεις με καρκίνωμα του θύμου. **ΑΠΟΤΕΛΕΣΜΑΤΑ** Το θύμωμα με λεμφοκυτταρική επικράτηση ήταν συχνότερο (44%). Ένας ασθενής με βαριά μυασθένεια και θύμωμα από λεμφοκύτταρα και επιθηλιακά κύτταρα παρουσίασε θύμωμα στον υπεζωκότα και τον πνεύμονα 6, 11 και 12 χρόνια μετά από τη θυμεκτομή. Η αφαίρεση του έκτοπου θυμώματος έδειξε ατυπία των επιθηλιακών κυττάρων όμοια με μια περίπτωση ενδοτραχειακού θυμικού καρκινώματος. Από τους 26 ασθενείς με βαριά μυασθένεια, 88% ήταν θετικοί για αντίσωμα κατά του AChR, ενώ 65% είχαν αυξημένες τιμές αντισώματος κατά του AChR πριν από τη θυμεκτομή. Ένας ασθενής με βαριά μυασθένεια παρουσίαζε αντίσωμα κατά της CL-β₂GP1. Παράταση του aPTT (42,8–200,0 sec) διαπιστώθηκε στους ασθενείς με βαριά μυασθένεια. Στους 26 ασθενείς με μυασθένεια εμφανίστηκε θρόμβωση των φλεβών (6), θρόμβωση της πυλαίας (1), έμφραγμα μυοκαρδίου (1), θρόμβωση των εν τω βάθει φλεβών μετά από εγκεφαλικό έμφρακτο (1), πνευμονική εμβολή (1) και ειλεός (2) σε διάστημα 5 ημερών μέχρι 6 έτη μετά από τη θυμεκτομή. **ΣΥΜΠΕΡΑΣΜΑΤΑ** Η θρόμβωση των ηπατικών φλεβών και ο ειλεός μετά από θυμεκτομή δεν συνοδεύονται από σημαντικά εμβολικά επεισόδια. Η αυτοανοσία βελτιώθηκε με μείωση των αντισωμάτων κατά του AChR ένα μήνα μετά από τη θυμεκτομή. Έκτοπο θύμωμα στον υπεζωκότα και τον πνεύμονα βρέθηκε σε έναν ασθενή με επανειλημμένες υποτροπές και προοδευτικά επιδεινούμενη ατυπία.

Λέξεις ευρητηρίου: Βαριά μυασθένεια, Έκτοπο θύμωμα, Θυμεκτομή, Θύμωμα, Καρκίνωμα θύμου

References

- CONTI-FINE BM, MILANI M, KAMINSKI HJ. Myasthenia gravis: Past, present, and future. *J Clin Invest* 2006, 116:2843–2854
- KAWAGUCHI N, KUWABARA S, NEMOTO Y, FUKUTAKE T, SATOMURA Y, ARIMURA K ET AL. Treatment and outcome of myasthenia gravis: Retrospective multi-center analysis of 470 Japanese patients, 1999–2000. *J Neurol Sci* 2004, 224:43–47
- GILBERT D, LECCHI M, ARNAUDEAU S, BERTRAND D, DEMAUREXA N. Local and global calcium signals associated with the opening of neuronal α7 nicotinic acetylcholine receptors. *Cell Calcium* 2009, 45:198–207
- MYGLAND A, TYSNES OB, MATRE R, VOLPE P, AARLI JA, GILHUS NE. Ryanodine receptor autoantibodies in myasthenia gravis patients with a thymoma. *Ann Neurol* 1992, 32:589–591
- ROMI F, AARLI JA, GILHUS NE. Myasthenia gravis patients with ryanodine receptor antibodies have distinctive clinical features. *Eur J Neurol* 2007, 14:617–620
- TAKAMORI M. Autoantibodies against TRPC3 and ryanodine receptor in myasthenia gravis. *J Neuroimmunol* 2008, 200:142–144
- BARRITT GJ, CHEN J, RYCHKOV GY. Ca²⁺-permeable channels in the hepatocyte plasma membrane and their roles in hepatocyte physiology. *Biochim Biophys Acta* 2008, 1783:651–672
- SUN J, YAMAGUCHI N, XU L, EU JP, STAMLER JS, MEISSNER G. Regulation of the cardiac muscle ryanodine receptor by O(2) tension and S-nitrosoglutathione (dagger). *Biochemistry* 2008, 47:13985–13990
- AROMATARIS EC, CASTRO J, RYCHKOV GY, BARRITT GJ. Store-operated Ca²⁺ channels and stromal interaction molecule 1 (STIM1) are targets for the actions of bile acids on liver cells. *Biochim Biophys Acta* 2008, 1783:874–885
- HEYMAN SRG, De RAEVE H, MERCELIS R, De POOTER C, VAN SCHIL P. Recurrent myasthenia gravis due to a pleural implant 3 years after radical thymectomy. *Ann Thorac Surg* 2008, 86:299–301
- LUCCHI M, BASOLO F, MUSSI A. Surgical treatment of pleural recurrence from thymoma. *Eur J Cardiothorac Surg* 2008, 33:707–711
- MYERS PO, KRITIKOS N, BONGIOVANNI M, TRIPONEZ F, COLLAUD S, PACHE J ET AL. Primary intrapulmonary thymomas: A systematic review. *EJSO* 2007, 33:1137–1141

Corresponding author:

T. Nakatsuji, Department of Transfusion Cell Therapy, Hamamatsu University School of Medicine, 1-20-1 Handayama, Higashi-ku, Hamamatsu 431-3192, Japan
e-mail: nh80415@hama-med.ac.jp