

## CONTINUING MEDICAL EDUCATION ΣΥΝΕΧΙΖΟΜΕΝΗ ΙΑΤΡΙΚΗ ΕΚΠΑΙΔΕΥΣΗ

### Surgery Quiz – Case 4

An 83 year-old female patient presented to the emergency department with complaint of acute lower abdominal pain, that began the last 24 hours, gradually worsened and was accompanied by nausea and vomiting the last couple of hours. The pain was severe, steady, unremitting, localized to the hypogastric region and aggravated by motion, coughing and deep breathing. Her medical history included diabetes mellitus, hypertension and chronic atrial fibrillation, for which she received drug therapy, including an ACE inhibitor, oral hypoglycemic and warfarin (5 mg/day). Prior surgical operations included left femoral hernia repair and appendectomy, during her adolescence. During the past 7 days, she experienced recurrent bouts of forceful coughing, attributed to an upper respiratory tract infection, for which she was treated conservatively by her personal physician. Physical examination revealed sinus tachycardia (vitals: HR 100 bpm, BP 120/74 mmHg), normal bowel sounds at auscultation, abdominal tenderness, muscular rigidity and guarding on palpation in the right lower quadrant and suprapubic region. Chest and abdominal X-ray, as well as urine analysis, were unremarkable. CBC and blood chemistry were unrevealing, apart from a low Ht (30.3%; Hb: 13.3 g/dL) with normal PLT (210,000/ $\mu$ L) and an INR of 3.05. Gynecologic consult (bimanual examination and endocervical ultrasound) demonstrated no underlying pathology. The patient underwent, the same day, an abdominal CT that revealed a hypodense mass (12x8.5x5.5 cm) on the right rectus sheath (fig.1). She was admitted in our clinic for expectant therapy, close observation and follow-up. Twelve hours later her clinical picture did not improve and an ecchymosis developed in the hypogastric region, with a further drop in her Hb level (11 g/dL). The patient underwent evacuation of her hematoma, under local anesthesia, via a right lower quadrant incision, parallel to the inguinal ligament. The postoperative period was unremarkable and she was discharged, in a relatively good clinical condition, at the 6th postoperative day.

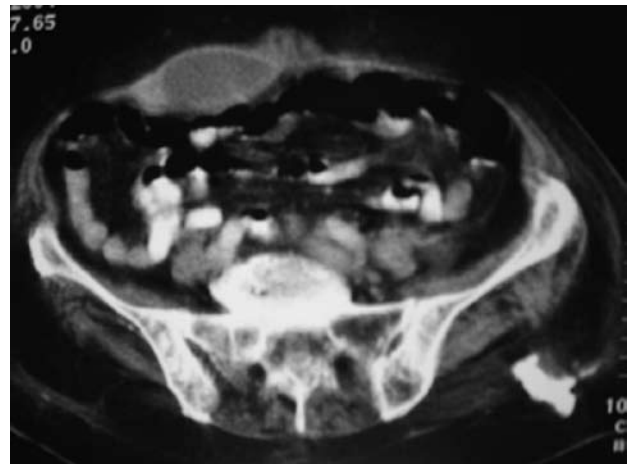
#### Comment

RSH is unique not only because of its rarity, but also because it is usually misdiagnosed as a cause of acute abdominal pain, mimicking other conditions such as abdominal tumors or inflammatory diseases. It results from bleeding in the rectus sheath due to damage of the superior/inferior epigastric artery or their branches, or even as a result of direct tear to the rectus abdominis muscle. Most RSH

ARCHIVES OF HELLENIC MEDICINE 2009, 26(1):133–134  
ΑΡΧΕΙΑ ΕΛΛΗΝΙΚΗΣ ΙΑΤΡΙΚΗΣ 2009, 26(1):133–134

L. Lekakos,  
G. Tsourouflis,  
N. Karidis,  
G. Kouraklis

Second Department of Propedeutic  
Surgery, Medical School, University of  
Athens, "Laiko" General Hospital, Athens,  
Greece



**Figure 1.** Abdominal CT showing a hypodense mass on the right rectus abdominus.

occur below the arcuate line where the posterior rectus sheath is deficient and the epigastric vessels are relatively fixed and prone to shearing. Below this line there is only transversalis fascia between the peritoneum and the posterior rectus sheath, therefore rupture of an epigastric vessel or muscle within the sheath can mimic acute abdomen (most RSH occur in the lower abdomen from the inferior epigastric artery). Above the semicircular line (semilunar fold of Douglas) the non-distensible nature of the rectus sheath protects against accumulation of blood (tamponades bleeding and limits expansion).

Early, but equivocal signs and symptoms, such as abdominal pain and tenderness, voluntary guarding can be severe enough and mimic peritonitis. Other physical findings include fever, nausea, vomiting, tachycardia, a palpable non-pulsatile abdominal mass, signs of local peritoneal irritation, abdominal distension and cramping. Abdominal wall ecchymosis is a later sign that can occur in the flanks or periumbilical region causing Grey-Turner and Cullen sign, respectively. In some cases RSH can expand into the perivesical and preperitoneal space resulting in decreased Hct,

although hemodynamic instability (hypovolemic shock) is uncommon. Lastly, patients with RSH can exhibit a positive Carnett's (a test to help determine whether the tenderness is intraperitoneal or arising from the abdominal wall: tenderness arising inside the abdominal cavity is reduced when the abdominal masses are tensed by lifting head and shoulders off the examination couch; in contrast, this manoeuvre worsens or has no effect on tenderness if the pathology is arising from the abdominal wall) and Fothergill's test (positive when RSH produces a mass that doesn't cross the midline and remains palpable, when the patient tenses his rectus abdominis muscle by touching his chest with his chin).

Etiology of RSH is either posttraumatic (blunt, penetrating trauma) or spontaneous. The most common cause in young women is pregnancy, in young men trauma/muscle exertion and in the elderly poorly controlled anti-coagulation therapy. Other causes include iatrogenic damage (laparotomy, laparoscopy, needle punctures, paracentesis), hypertension, medical injections (LMWH) and increased abdominal pressure (muscle contraction-stretching) from straining, coughing etc. Despite the fact that most cases are self-limiting, RSH can lead to an overall mortality as high as 4%. Patients on anticoagulation therapy, is reported to have a mortality rate as high as 25%, due to the larger size of hematoma, increased age and co-morbidity of the patient. Mortality also increases because RSH is underdiagnosed and difficult to diagnose, resulting in a large number of unnecessary laparotomies, in a subset of patients that are poor surgical candidates. Furthermore, RSH in pregnancy –usually 3rd trimester– can be associated with a fetal mortality rate of up to 25%.

Both ultrasonography and CT are used in the diagnosis of RSH. CT is superior to ultrasound in the following aspects: (a) more sensitive and specific, (b) can rule out other abdominal pathology and aid in the differential diagnosis (twisted ovarian cyst, appendiceal

abscess, strangulated Spigelian hernia), (c) provide information on whether the bleeding is active or not, (d) differentiate intraperitoneal from extraperitoneal lesion, (e) localize and evaluate size and dimensions of lesion and (f) classify RSH (type I RSH are minor hematomas within the muscle, do not require hospitalization and resorb spontaneously within 30 days, type II RSH are moderate in size, within the muscle, but bleed between transversalis fascia and muscle, require hospitalization and resorb in 3 months, and type III that are severe, located between transversalis fascia and muscle, anterior to the peritoneum and urinary bladder, require hospitalization and resorb in 3 months).

The majority of RSH are treated conservatively with analgesia and treatment of underlying condition. When necessary, cessation of anticoagulation, fluid resuscitation and reversal of anti-coagulation and or antiplatelet therapy is instituted, with the expert advice of a hematologist. In an unstable patient who is hemodynamically compromised, with active bleeding, radiological embolization should be attempted without delay. If this fails, the next step is ligation of the bleeding vessel, via an open surgical approach or through image guidance, percutaneously. Surgical evacuation is indicated only if hematoma is very large, bleeding is persistent, or rarely abdominal compartment syndrome is suspected, otherwise the potential of tamponade effect is lost.

Corresponding author:

G. Kouraklis, Second Department of Propedeutic Surgery, Medical School, University of Athens, "Laiko" General Hospital, 17 Agiou Thoma street, GR-115 27 Athens, Greece, Tel.: +30 210 74 56 346, e-mail: gkouraklis@hotmail.com