

CONTINUING MEDICAL EDUCATION ΣΥΝΕΧΙΖΟΜΕΝΗ ΙΑΤΡΙΚΗ ΕΚΠΑΙΔΕΥΣΗ

Oral Medicine and Pathology Quiz – Case 5

A 60-year-old male was referred to our clinic for evaluation of a mass in his tongue, which the patient reported as inflammation. The lesion was first noticed by his dentist two months ago and considered to be due to local trauma caused by a “sharp-edged” tooth, which was extracted without improvement. The patient was a heavy smoker (two packs per day) and his medical history was important for hypertension, epilepsy and specific food allergy (controlled by medications).

On clinical examination, a firm, ulcerated mass with ill-defined, rolled borders, measuring 3.5×2.0×1.5 cm, was noticed on the left lateral and ventral surface of the tongue. The lesion was partially covered by pseudomembrane, was associated with adjacent areas of leukoplakia and was indurated and painful on palpation (fig. 1). Partial biopsy of the lesion was performed and the specimen was submitted for histopathological examination, which revealed infiltration of the connective tissue by islands of well-differentiated squamous cells forming keratin pearls (fig. 2).

Comment

Oral squamous cell carcinoma (OSCC) represents more than 90% of all cases of oral cancer, which is one of the ten most common types of cancer worldwide. Incidence of OSCC varies according to age, gender, race, and socioeconomic factors and shows great

disparities among different countries, being the most common type of cancer in India and some other Asian countries.

The risk of OSCC increases with age, with the majority of cases occurring in middle-aged and older individuals. However, a tendency for increased incidence among young individuals (below age 40) has been recently recorded. Males are affected with OSCC at a ratio of 2:1 or 3:1 in comparison to females, although this ratio varies among different countries and populations depending upon the relative exposure of the two genders to the etiologic factors of OSCC development.

Tobacco smoking and alcohol intake have a strong interactive effect on the risk of OSCC. Continuous exposure to sun irradiation is mainly responsible for development of OSCC of the lower lip. Various other local and systemic factors have been incriminated, although their contribution may be weak or controversial. In recent years, the role of HPV viruses has been under intense investigation. Also, OSCC is now considered to be the result of a multistep process which involves a number of aberrant genetic events.

OSCC can develop anywhere in the oral cavity. The most common sites are the lateral borders and ventral surface of the tongue, the floor of the mouth and the vermillion of the lower lip. The lesions may appear to be endophytic (ulcers with irregular, rolled borders)

ARCHIVES OF HELLENIC MEDICINE 2008, 25(6):840–841
ΑΡΧΕΙΑ ΕΛΛΗΝΙΚΗΣ ΙΑΤΡΙΚΗΣ 2008, 25(6):840–841

N.G. Nikitakis,
S. Titsinidis,
A. Sklavounou-Andrikopoulou

Department of Oral Medicine and
Pathology, School of Dentistry, National
and Kapodistrian University of Athens,
Athens, Greece

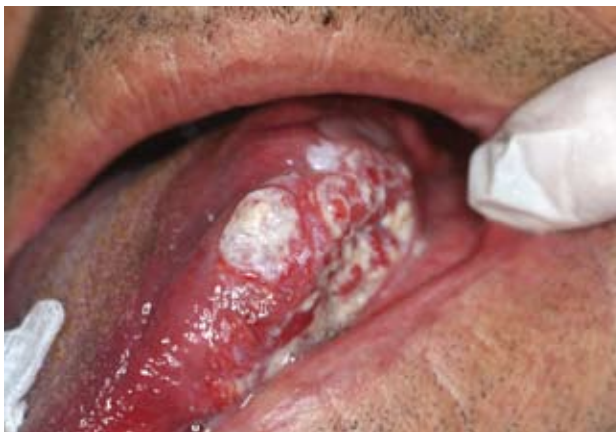

Figure 1

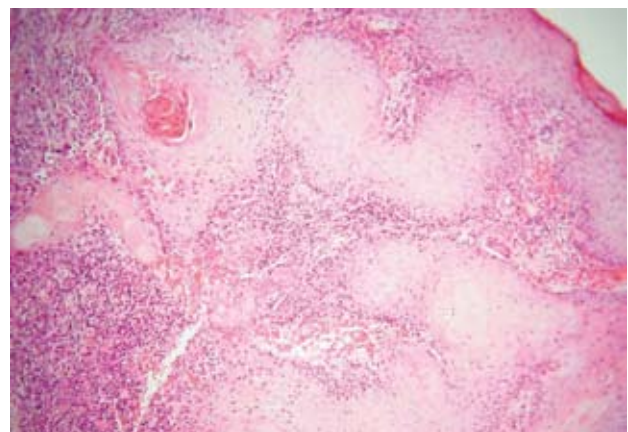


Figure 2

or exophytic (mass-like growths with surface irregularities and or ulcerations); induration on palpation is another common feature. Leukoplakia or erythroplakia may also harbor invasive cancer but usually correspond to precancerous alterations that frequently precede or accompany OSCC, an important feature that may allow prevention and or early detection of malignant transformation. OSCC lesions are frequently asymptomatic at the initial stages, highlighting the need for careful oral examination and screening by adequately trained dental and medical professionals. During the progression of the tumor, symptoms of pain, hemorrhage, dysphagia, and tongue movement limitation may develop.

Histopathologically, OSCC are characterized by the invasion of the connective tissue by malignant epithelial cells, organized into sheets, islands, or cords. According to the degree of differentiation, the tumors are graded as well, moderately or poorly differentiated.

Treatment of OSCC usually involves surgery (with or without neck dissection), radiotherapy or combinations thereof. Chemotherapy is not effective as a monotherapy against OSCC but is used as an adjunctive or palliative treatment. New investigative treatments include immunotherapy, gene and molecular targeted therapy. Treatment planning requires a multidisciplinary approach (tumor board). Various factors affect prognosis and influence the choice

of treatment, such as the site and histological grade of the primary tumor and the patient's age and general medical condition. However, the most important parameter that determines prognosis and guides treatment is clinical stage (TNM system).

OSCC has a substantial risk of development of regional lymph node and, later on, distant metastasis. In general, early-stage OSCC have high survival rates, which drop dramatically as disease progresses; the overall 5-year survival rate is about 50%. Presence of a single metastatic lymph node reduces survival by 50%. Elimination of the major causative factors like smoking, alcohol consumption and sun exposure (when applicable) is necessary. Frequent lifelong follow-up examination of these patients by an expert clinician is mandatory for prompt detection and management of possible recurrences or second primary tumors.

Corresponding author:

N.G. Nikitakis, Department of Oral Pathology and Medicine, School of Dentistry, National and Kapodistrian University of Athens, 2 Thivon street, GR-115 27 Athens, Greece, tel: +30 210 74 61 003, fax: +30 210 74 61 220
e-mail: nnikitakis1@yahoo.com